

## Pulmonary alveolar proteinosis: prolonged spontaneous remission in two patients

M.A. Martínez-López, G. Gómez-Cerezo, C. Villasante, F. Molina,  
S. Diaz, J. Cobo, C. Medraño

*Pulmonary alveolar proteinosis: prolonged spontaneous remission in two patients. M.A. Martínez-López, G. Gómez-Cerezo, C. Villasante, F. Molina, S. Diaz, J. Cobo, C. Medraño.*

**ABSTRACT:** Pulmonary alveolar proteinosis is a rare idiopathic diffuse airspace disease characterized by intra-alveolar accumulation of large quantities of lipoproteinaceous material, with preservation of the lung interstitium. The clinical course of pulmonary alveolar proteinosis is variable. Spontaneous resolution is known to occur in up to a quarter of the cases. We describe two patients with untreated pulmonary alveolar proteinosis who experienced complete clinical, functional and radiographic resolution. In follow-up periods of fourteen and six years, both patients have remained asymptomatic.

*Eur Respir J., 1991, 4, 377-379.*

Dept of Internal Medicine, Hospital "La Paz",  
Universidad Autónoma de Madrid, Spain.

Correspondence: Dr M.A. Martínez-López, Avda  
Llano Castellano 3, 5<sup>o</sup>B Madrid 28034, Spain.

Keywords: Bronchopulmonary lavage; pulmonary  
alveolar proteinosis.

Received: February 1, 1990; accepted after revision  
September 14, 1990.

Pulmonary alveolar proteinosis (PAP) is an uncommon disorder described thirty one years ago by ROSEN *et al.* [1]. The disease, which is of unknown aetiology, is characterized by deposition within the air spaces of acid Schiff-positive proteinaceous material that is rich in lipid. The diagnosis is confirmed by typical electron-microscopic findings in sputum, lung washings, or lung biopsy specimens. Approximately three quarters of the patients require therapeutic bronchoalveolar lavage which provides symptomatic, physiological, and radiological improvement in most cases [2]. Nevertheless, spontaneous complete resolutions in untreated PAP do occur. This report describes two patients who had a spontaneous complete prolonged remission.

### Case reports

#### Patient 1

A 40 yr old nonsmoking housewife was admitted to the hospital because of increasing dyspnoea. Two months earlier, she began to have exertional dyspnoea, cough and production of white sputum. On examination she was severely dyspnoeic. The respiratory rate was 40 and the pulse was 95 per minute. The lungs were clear and the heart sounds were normal, as were the vascular system and extremities. The haematocrit reading was 36%, and the white cell count was  $7.6 \times 10^9/l^{-1}$ , with a

normal differential count. The serum lactic dehydrogenase level was in the normal range. Skin tests with tuberculin (PPD, 5TU) and mumps antigen were negative. Microscopic examination of stained specimens of sputum disclosed no acid-fast bacilli on three occasions, and a culture of sputum yielded a normal throat flora. A chest roentgenogram (fig. 1) showed bilateral alveolar infiltrates. Pulmonary function tests (table 1) demonstrated mild restrictive disease with a reduced diffusing capacity. An open lung biopsy demonstrated PAS-positive proteinaceous material filling normal-appearing alveoli.

The patient had considerable symptomatic and radiographic improvement over the ensuing months. Two years later she experienced a complete clinical, functional, and radiological remission. At the most recent follow-up, fourteen years after diagnosis, she showed no further evidence of lung disease.

#### Patient 2

A 34 yr old clerical worker was admitted to hospital because of exertional dyspnoea. He was well until three months earlier, when he had a brief illness characterized by fever and malaise; the illness was followed by increasing dyspnoea. On physical examination the patient appeared well and in no distress. Respiratory rate was 20 per minute at rest. Fine inspiratory crackles were heard over the lower one-third of both lungs. The

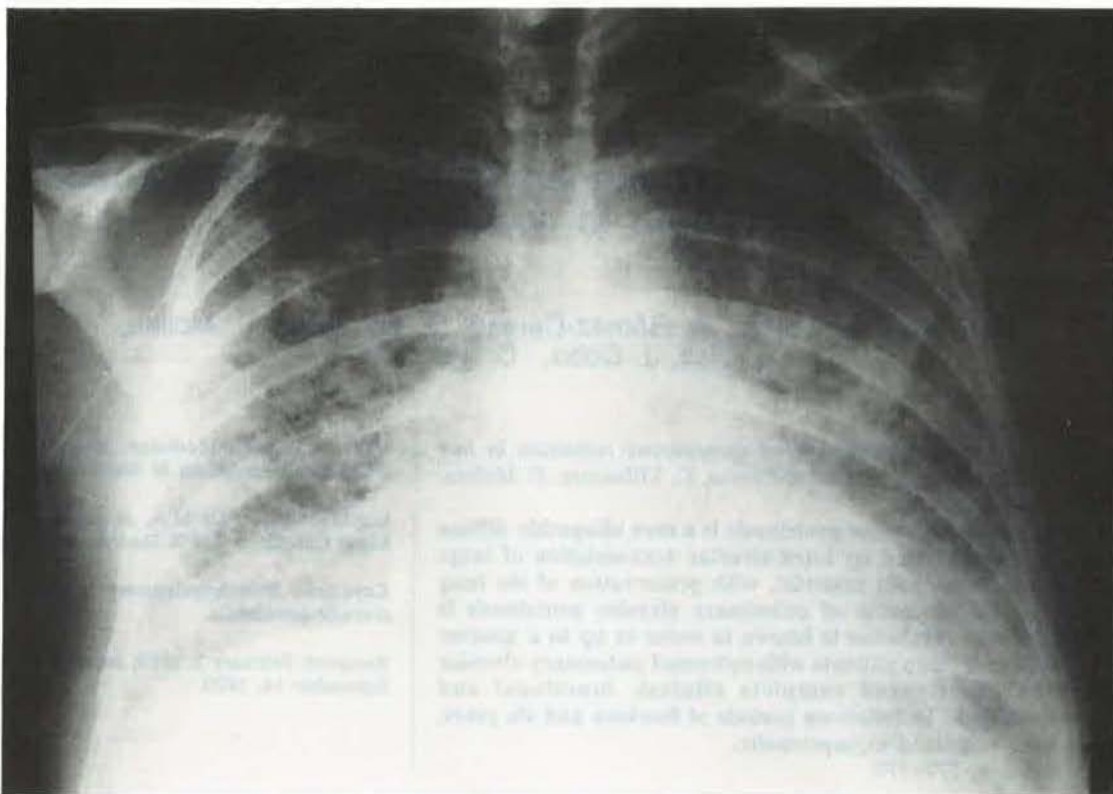


Fig. 1. - Chest X-ray (patient 1) at the time of diagnosis, showing diffuse bilateral alveolar infiltrates.

Table 1. - Pulmonary function test results

	Patient 1		Patient 2	
	A	B	A	B
FVC % pred	72	91	74	86
FEV <sub>1</sub> % pred	78	90	62	79
FEV <sub>1</sub> /FVC %	82	76	70	77
TLC % pred	64	81	70	82
RV % pred	57	85	98	90
Dlco % pred	39	81	60	83
<b>Arterial blood gas values (room air)</b>				
Pao <sub>2</sub> kPa	5.7	10.2	8.1	11.2
Paco <sub>2</sub> kPa	4.0	4.6	3.6	5.3
pH	7.4	7.4	7.4	7.4
HCO <sub>3</sub> <sup>-</sup> mmol·l <sup>-1</sup>	23	21.8	21	23

A: tests performed at time of diagnosis; B: tests performed after total resolution of the disease (patient 1: two years after diagnosis; patient 2: one year after diagnosis); FVC: forced vital capacity; FEV<sub>1</sub>: forced expiratory volume in one second; TLC: total lung capacity; RV: residual volume; Dlco: carbon monoxide diffusing capacity; Pao<sub>2</sub>: arterial oxygen tension; Paco<sub>2</sub>: arterial carbon dioxide tension; HCO<sub>3</sub><sup>-</sup>: standard bicarbonate.

cardiovascular system and extremities were normal. The haematocrit reading was 54%, the white blood cell count was  $6.2 \times 10^9 \cdot l^{-1}$ , with a normal differential count, and the level of lactic dehydrogenase was  $6.21 \mu\text{mol} \cdot l^{-1}$ . Skin tests with tuberculin (PPD, 5TU) and mumps antigen were negative.

Microscopic examination of stained specimens of sputum disclosed no acid-fast bacilli on three occasions,

and a culture of sputum yielded a normal throat flora. A chest roentgenogram showed a mixed interstitial and alveolar process in both lungs, more prominent at the bases. Pulmonary function tests (table 1) demonstrated moderate restrictive disease with a reduced diffusing capacity. A diagnostic bronchoscopy combined with segmental lavage and transbronchial biopsy yielded equivocal results. The patient underwent open lung

biopsy which demonstrated granular eosinophilic PAS-positive material filling normal-appearing alveoli, consistent with PAP.

The dyspnoea and radiological infiltrates resolved within 6 months in the absence of therapy. One year later, his pulmonary function tests results were normal. At the most recent follow-up, six years after diagnosis, he remained in complete remission.

### Discussion

The natural history of PAP in adults is variable [2]. These two cases illustrate a rather unusual, although well-known, clinical course for this disease. Both patients had a spontaneous prolonged clinical, functional and radiological remission. Interestingly, a retrospective review of our hospital records through 1989 revealed no other patients with the diagnosis of PAP.

The disease generally had a gradual onset over a period of many months, but there can be a more abrupt onset with a rapid course [3]. If there is initial severe disease or progressive worsening with significant hypoxaemic and shunting, whole lung lavage is indicated. Approximately three quarters of patients require therapeutic lavage, which provides symptomatic and functional improvement in nearly all cases [4, 5].

The possibility of spontaneous remission also exists. In the original report of PAP, resolution was noted in 6 of 27 patients [1]. In a prospective study by KARIMAN *et al.* [2], 5 of 23 patients experienced spontaneous remission. In the review of 139 cases of PAP by DAVIDSON and MACLEOD [6], 34 patients (24%) underwent complete resolution. WILSON and ROGERS [7] described a patient who had an 18 yr spontaneous remission before presenting with disabling symptoms.

In the patients who experience resolution, lung functions return to normal with 1–3 yrs after the diagnosis of PAP [2], as occurred in these two cases.

Finally, the potential for prolonged spontaneous remission should always be kept in mind in the evaluation of patients with this disease, particularly before making therapeutic decisions.

### References

1. Rosen SH, Castleman B, Liebow AA. – Pulmonary alveolar proteinosis. *N Engl J Med*, 1958, 82, 1014–1016.
2. Kariman K, Kylstra JA, Spock A. – Pulmonary alveolar proteinosis: prospective clinical experience in 23 patients for 15 years. *Lung*, 1984, 162, 223–231.
3. Prakash UBS, Barham SS, Carpenter HA, Dines DE, Marsh HM. – Pulmonary alveolar phospholipoproteinosis: experience with 34 cases and a review. *Mayo Clin Proc*, 1987, 62, 499–518.
4. Ramirez RJ. – Pulmonary alveolar proteinosis: treatment by massive bronchopulmonary lavage. *Arch Intern Med*, 1967, 119, 147–156.
5. Claypool WD, Rogers RM, Matuschak GM. – Update on the clinical diagnosis, management and pathogenesis of pulmonary alveolar proteinosis (phospholipidosis). *Chest*, 1984, 85, 550–558.
6. Davidson JM, Macleod WM. – Pulmonary alveolar proteinosis. *Br J Dis Chest*, 1969, 63, 13–28.
7. Wilson DO, Rogers RM. – Prolonged spontaneous remission in a patient with untreated pulmonary alveolar proteinosis. *Am J Med*, 1987, 82, 1014–1016.

*Protéinose alvéolaire pulmonaire: rémission spontanée prolongée chez deux patients. M.A. Martínez-López, J. Gómez-Cerezo, C. Villasante, F. Molina, S. Diaz, J. Cobo, C. Medrafto.*

**RÉSUMÉ:** La protéinose alvéolaire pulmonaire est une affection bizarre, idiopathique et diffuse des espaces aériens caractérisée par l'accumulation intraalvéolaire de nombre aux matériaux lipoprotéinacés qui respecte l'interstitium pulmonaire. Le décours clinique de la protéinose alvéolaire pulmonaire est variable et nous savons que la résolution spontanée existe jusqu'à 25 pour cent des patients. Nous décrivons deux patients dont la maladie a été suivie d'une rémission spontanée clinique, radiologique et fonctionnelle. Pendant les périodes de suivi pendant quatorze et six ans, les patients ont été asymptomatiques. *Eur Respir J.*, 1991, 4, 377–379.