



“A neutrophil elastase inhibitor prevents bleomycin-induced pulmonary fibrosis in mice.” Akihiro Takemasa, Yoshiki Ishii and Takeshi Fukuda. *Eur Respir J* 2012; 40: 1475–1482.

In the originally published version of this article, it has been found that incorrect representative images were used for the sivelestat group in figure 1. These incorrect images (fig. 1b and f) should be replaced with the correct ones, as shown below. The sivelestat group demonstrated minimum inflammatory and fibrotic changes, as was found in the control group; therefore, the messages and conclusions of the manuscript remain the same. The authors apologise for this error.

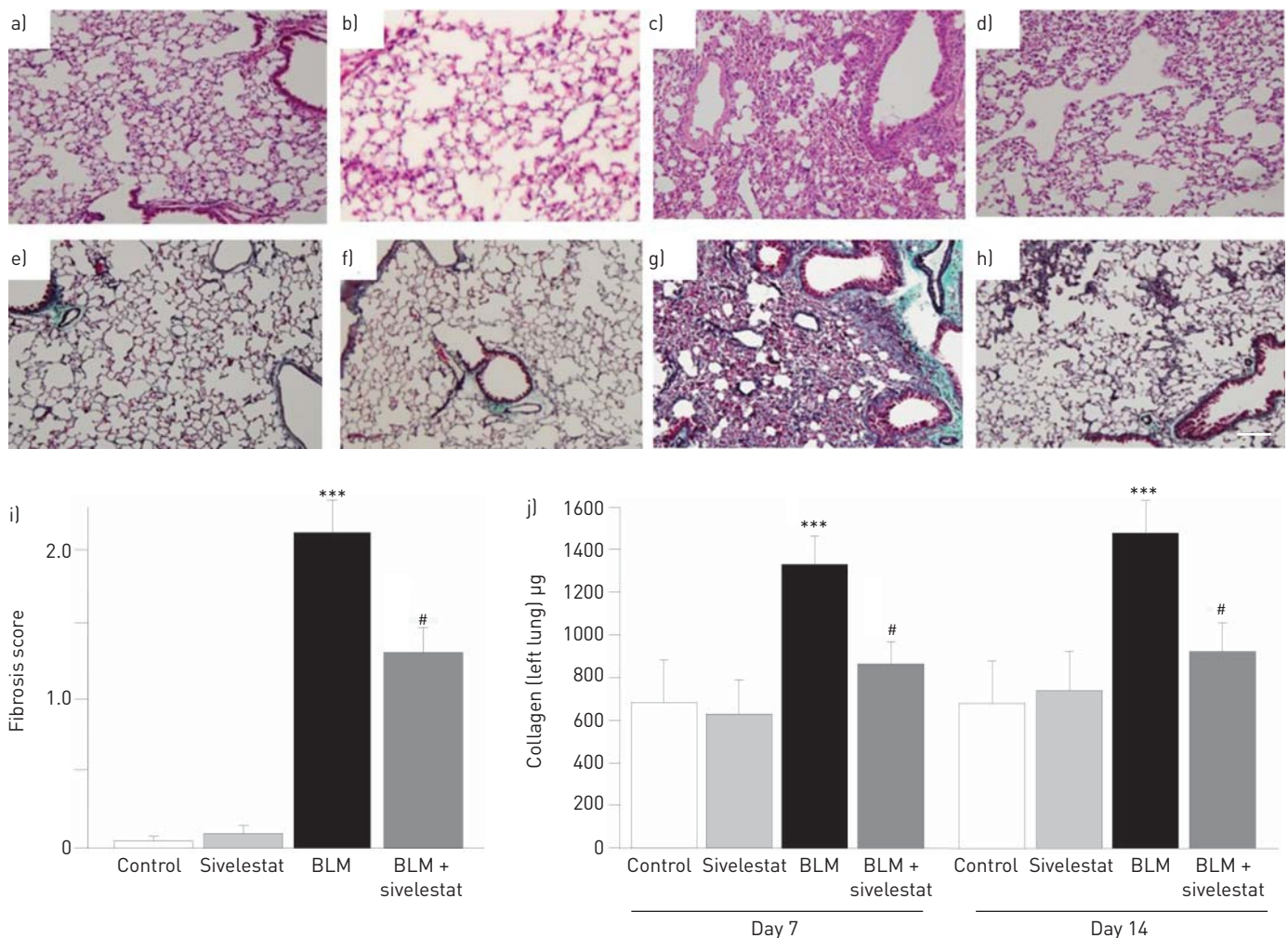


FIGURE 1 The antifibrotic effects of sivelestat were observed by histological examination. Representative pathological findings in lung tissue stained with a–d) hematoxylin–eosin and e–h) Masson’s trichrome on day 14 after bleomycin (BLM) instillation. a and e) Control group; b and f) sivelestat group; c and g) BLM group; d and h) BLM+sivelestat group. Sivelestat (100 mg·kg<sup>-1</sup>) was given 3 h after intratracheal BLM instillation (5 mg·kg<sup>-1</sup>) and daily from day 2 to 14 after intratracheal BLM instillation. Scale bar=200 µm. i) Fibrosis scoring based on severity and area of fibrosis on day 14. The fibrosis score of mice treated with sivelestat 100 mg·kg<sup>-1</sup> without BLM showed no significant change compared with that of the untreated control mice. Sivelestat 100 mg·kg<sup>-1</sup> significantly alleviated BLM-induced pulmonary fibrosis. j) Collagen content in lung tissues. BLM augmented the lung collagen content on day 7 as well as day 14. Sivelestat 100 mg·kg<sup>-1</sup> significantly alleviated the increased collagen content on day 7 as well as day 14. Data are presented as mean±SEM; n=10 in each group. \*\*\*, p<0.001 versus control group; #: p<0.001 versus BLM group.