

Intraventricular rifampicin in severe tuberculous meningo-encephalitis

W. Vincken*, M. Meysman*, D. Verbeelen**, S. Lauwers*, J. D'Haens**

Intraventricular rifampicin in severe tuberculous meningo-encephalitis. W. Vincken, M. Meysman, D. Verbeelen, S. Lauwers, J. D'Haens

ABSTRACT: We present a patient acutely ill from severe tuberculous meningo-encephalitis, in whom acute hepatic and renal failure, due to intercurrent septic shock, precluded the administration of full systemic dosage of antituberculous drugs. Daily direct intraventricular administration of 5 mg rifampicin, via a subcutaneous Ommaya reservoir connected to a catheter placed in the right lateral cerebral ventricle, resulted in rapid improvement without neurological sequelae. Intraventricular rifampicin administration for 50 consecutive days was well-tolerated without local or systemic side-effects.

In well-selected patients with severe tuberculous meningo-encephalitis, intraventricular rifampicin may safely and highly effectively be added to systemic antituberculous therapy.

Eur Respir J., 1992, 5, 891-893.

Depts of * Pneumology, ** Nephrology, * Microbiology and ** Neurosurgery, Academic Hospital, University of Brussels, Brussels, Belgium.

Correspondence: W. Vincken
Respiratory Division
AZ VUB, 101 Laarbeeklaan
B-1090 Brussels, Belgium

Keywords: Intraventricular administration
rifampicin
tuberculous meningitis

Received: November 21 1991

Accepted after revision April 6 1992

The mortality rate of tuberculous meningo-encephalitis remains high (20-33%) despite antituberculous drug therapy and up to one third of survivors manifest serious neurological sequelae. In a recent study [1], mortality was found to be higher when therapy was started during the first week of hospitalization than when it was started later (36 and 10% respectively). This may reflect rapid diagnosis of tuberculous meningitis in patients with more dramatic presentation; it also indicates that early institution of specific chemotherapy cannot prevent mortality in one third of advanced cases. Moreover, a substantial proportion of survivors treated early subsequently fail to show clinical improvement [2], probably due to the failure to rapidly control growth of *Mycobacterium tuberculosis* in the central nervous system (CNS), resulting in persistent ventriculitis, encephalitis and cerebral endarteritis.

With the exception of isoniazid, most first-line anti-tuberculous drugs do not penetrate the blood brain barrier (BBB) well, especially when meningeal inflammation is not prominent. Even in patients with inflamed meninges, cerebrospinal fluid (CSF) concentrations of rifampicin are only a fraction of plasma concentrations [3] and show wide interindividual variations, not always exceeding the minimal inhibitory concentration (MIC) of *M. tuberculosis* [4].

We present an acutely ill patient with severe tuberculous meningo-encephalitis, who rapidly recovered without neurological sequelae following direct intraventricular administration of rifampicin.

Case report

A 59 yr old man developed low-grade fever, malaise, weight loss and increasing dyspnoea in February

1989. The chest roentgenogram showed diffuse miliary nodular infiltration and direct examination of bronchoalveolar lavage fluid yielded acid-fast bacilli. The CSF was normal at that time. Oral rifampicin (600 mg·day⁻¹) and ethambutol (1,200 mg·day⁻¹) were started. Isoniazid was withheld because of abnormal liver function tests. The patient became afebrile and his general status and dyspnoea improved. However, on March 15 he developed high spiking fever and generalized malaise, followed by oliguria in subsequent days. On March 21, 1989 he was referred to the Intensive Care Unit of our hospital, extremely ill with high fever (continuously above 39°C), hypotension, tachycardia, tachypnoea, anuria, icterus and diffuse petechiae. Fine inspiratory rales were heard at the right lung base. Heart sounds were normal. The liver was enlarged and tender at palpation. Splenomegaly and adenopathy were not found. The chest roentgenogram showed an ill-defined acinar consolidation of the right lower lobe. Swan-Ganz catheterisation revealed increased cardiac output, low systemic vascular resistance and normal left and right cardiac filling pressures, compatible with a hyperdynamic septic state.

Blood examination indicated renal failure (urea 232 mg·dl⁻¹, creatinine 6.3 mg·dl⁻¹), metabolic acidosis (bicarbonate 14 mEq·l⁻¹, base excess -7.6 mEq·l⁻¹), respiratory alkalosis (arterial carbon dioxide tension (Paco₂) 23 mmHg (3.1 kPa)), arterial hypoxaemia (arterial oxygen tension (Pao₂) 66 mmHg (8.8 kPa) on 5 l nasal O₂·min⁻¹), hyponatraemia (127 mEq·l⁻¹), thrombocytopenia (66,000·mm³), leucocytosis (17,000·mm³ with 88% neutrophils showing toxic granulations), moderate anaemia (haemoglobin 10.9 g·dl⁻¹), abnormal liver tests (NH₃ 81 µg·dl⁻¹, bilirubin 4.8 mg·dl⁻¹, lactate dehydrogenase (LDH) 1,611 IU·l⁻¹, serum glutamic

oxalo-acetic transaminase (SGOT) 89 IU·l⁻¹, serum glutamic pyruvic transaminase (SGPT) 38 IU·l⁻¹, alkaline phosphatase 323 IU·l⁻¹, γ -glutamyl transferase (γ -GT) 144 IU·l⁻¹ as well as abnormal coagulation tests (prothrombin time 22%, fibrin degradation product (FDP) 80 μ g·ml⁻¹, fibrinogen 391 mg·dl⁻¹). The diagnosis of (presumed bacterial) right lower lobe pneumonia with septic shock, disseminated intravascular coagulation, and acute renal and hepatic failure was made. Initial therapy consisted of intravenous (*i.v.*) administration of fluid, dopamine, dobutamine, sodium bicarbonate, broad spectrum antibiotics (cefuroxime and netilmicin with monitoring of serum levels) coupled with haemodialysis. Rifampicin (600 mg·day⁻¹) and ethambutol (1,200 mg·day⁻¹) were continued intravenously. Septic shock was rapidly reversed and the next day the patient was afebrile. However, because of further deterioration of liver enzymes (SGOT and SGPT >300 IU·l⁻¹), rifampicin was replaced on March 23 by *i.v.* streptomycin 1 g·day⁻¹ given after haemodialysis according to plasma levels. Cultures of blood, urine and sputum repeatedly remained negative.

Four days later high fever suddenly recurred, accompanied by confusion, stupor and nuchal rigidity. A few hours later status epilepticus developed with generalized clonic-tonic seizures, controlled by *i.v.* diazepam and diphantoin. Computerized axial tomography (CAT) of the brain was normal. Lumbar puncture yielded clear microorganism-free CSF revealing a mononuclear pleocytosis (313 white blood cells (WBC)·mm³ with 81% lymphocytes), increased protein (125 mg·dl⁻¹) and relatively low glucose (103 mg·dl⁻¹ for a concurrent glycaemia of 254 mg·dl⁻¹). Acute tuberculous meningo-encephalitis was diagnosed and *i.v.* isoniazid (250 mg·day⁻¹) was added despite liver failure. Because the patient was moribund, it was decided to inject rifampicin directly intraventricularly to rapidly obtain high bactericidal activity in the CSF. After obtaining informed consent of the family, a catheter was placed under local anaesthesia in the frontal horn of the right lateral ventricle and connected to a subcutaneous Ommaya reservoir. Five mg of rifampicin (lyophilized powder, Rifadine®, Merrell-Dow) were dissolved in its solvents and diluted to 5 ml using saline. After checking that no precipitation occurred, this solution was transcutaneously injected in the subcutaneous Ommaya reservoir under strict aseptic conditions and then pumped into the right lateral ventricle by slow, repeated manual compression. Prior to rifampicin injection, 5 ml of CSF were withdrawn from the Ommaya reservoir for microbiological and chemical analysis. The intraventricular injections were repeated daily without any local or systemic side-effects and, over the next few days, resulted in a remarkable recovery of general clinical status and consciousness, and rapid disappearance of fever and nuchal rigidity. The CSF protein levels and leucocyte counts gradually normalized (fig. 1). On control brain CAT a hypodense zone had appeared in the left frontal lobe, consistent with tuberculous cerebral endarteritis and infarction.

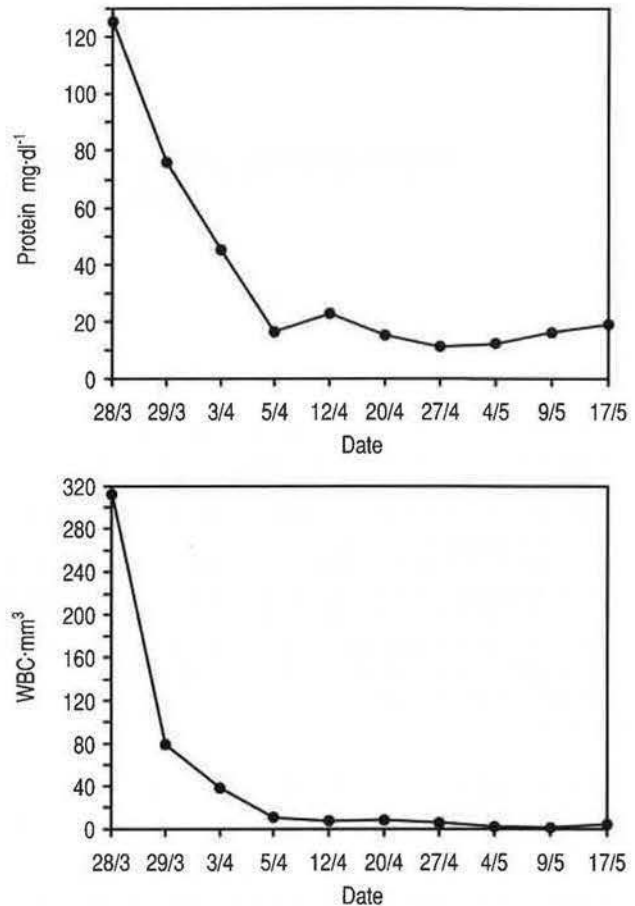


Fig. 1. — Decrease in protein concentration (upper panel) and white blood cell count (WBC) (lower panel) in the CSF following the start of daily intraventricular rifampicin administration on March 28, 1989. Dates between March 28 and May 17 along abscissa. CSF: cerebrospinal fluid.

Over the next weeks, renal function recovered, allowing discontinuation of haemodialysis; liver tests also gradually normalized. Cultures of several urine samples collected upon admission were now reported positive for *M. tuberculosis*.

After obtaining negative results for serum rifampicin antibodies, rifampicin was reintroduced orally on May 10 in gradually increasing doses up to 600 mg·day⁻¹. The intraventricular injections of rifampicin were discontinued 50 days after their commencement. On May 24 the patient was discharged in good general condition and without neurological sequelae with the following treatment: rifampicin 600 mg·day⁻¹, isoniazid 250 mg·day⁻¹, ethambutol 800 mg·day⁻¹ and pyridoxine 50 mg·day⁻¹. In March 1992, he is in good health, having discontinued his anti-tuberculous therapy since June 1990.

Discussion

This case report illustrates that intraventricular administration of rifampicin may favourably alter the outcome of severe acute tuberculous meningitis when

renal and hepatic failure preclude full systemic anti-tuberculous therapy.

Rifampicin is highly effective against *M. tuberculosis*. Its *in vitro* MIC varies between 0.05–0.2 $\mu\text{g}\cdot\text{ml}^{-1}$ [3]. Such concentrations are usually achieved in most organs [5]. Although this is also generally true for the CSF, in some instances effective CSF concentrations may not be obtained. Because of its high binding to plasma proteins, rifampicin does not penetrate the BBB in the absence of meningeal inflammation [6]. Even in patients with inflamed meninges, the CSF concentration of rifampicin only attains a fraction (1.5–10%) of that obtained in serum (4, 6, 7). Therefore, rifampicin concentrations are considerably lower in CSF than in other tissue fluids. Depending on the oral dose administered and the time at which CSF is tapped, mean rifampicin concentrations in CSF of patients with tuberculous meningitis vary between 0.054–0.4 $\mu\text{g}\cdot\text{ml}^{-1}$ [4, 6, 7]. Of importance, rifampicin concentrations in CSF show large and unpredictable interindividual variations, ranging from the single to the tenfold. This indicates that initial systemic administration of rifampicin does not invariably guarantee effective CSF concentrations. However, since rifampicin is cleared slower from the CSF than from serum, effective CSF concentrations are reached on subsequent days [4].

Whilst on treatment for tuberculosis our patient developed pneumonia with septic shock and acute renal and hepatic failure, precluding the administration of classic first-line antituberculous drugs such as isoniazid and rifampicin. After life-threatening septic shock had been successfully managed, he acutely developed tuberculous meningo-encephalitis whilst on systemic treatment with streptomycin and ethambutol, drugs known to fail to penetrate the BBB well. To ensure highly effective CSF antituberculous drug concentrations, apart from *i.v.* isoniazid, a first-line drug that penetrates the BBB well, rifampicin was injected directly intraventricularly *via* a subcutaneous Ommaya reservoir [8] connected to a catheter placed in the right lateral cerebral ventricle. This injection site allows repetitive daily injections of small doses (5 mg) for prolonged periods without patient discomfort, and also ensures effective CSF concentrations and good distribution of rifampicin in all compartments of the CSF. Indeed, 80–90% of CSF is secreted by the choroid plexus in the lateral ventricles and hence flows through the ventricular system into the cerebellomedullary cisterns, from where it reaches the subarachnoid space around the spinal cord and both cerebral hemispheres. Based on a theoretical CSF volume of 150 ml and taking into account a daily CSF production of 500–1,000 ml, the injection of only 5 mg rifampicin ensures peak CSF concentrations by far exceeding the MIC of *M. tuberculosis*. Advantages of the intraventricular catheter are that it can also serve to monitor intracranial pressure and may be used for local corticotherapy (which we did not apply in this patient).

The intraventricular route has previously been used for antibiotherapy of severe Gram-negative meningitis

and ventriculitis in infants [9] and for chemotherapy of carcinomatous meningitis [10]. Furthermore, we have previously successfully used the intraventricular administration of rifampicin in a patient with cerebral tuberculomas, tuberculous meningitis and cerebral endarteritis due to an isoniazid and streptomycin resistant *M. tuberculosis* [11].

In conclusion, the present case demonstrates that prolonged intraventricular administration of rifampicin can be safely and effectively added to the systemic treatment of tuberculous meningo-encephalitis, in well-selected patients in whom: 1) full systemic dosage cannot be achieved (*e.g.* in case of hepatic failure or suspected rifampicin hypersensitivity); 2) higher than usual CSF concentrations are needed (*e.g.*, in the case of infection with relatively resistant or atypical Mycobacteria); and 3) for bypassing the BBB when meningeal inflammation is not a prominent part of CNS tuberculosis (*e.g.* cerebral tuberculoma or infarction due to tuberculous endarteritis).

Acknowledgements: The authors thank M. Dufour for referring the patient and H. De Backer and A. Coppens for secretarial assistance in preparing this manuscript.

References

1. Ogawa SK, Smith MA, Brennessel DJ, Lowy FD. – Tuberculous meningitis in an urban medical center. *Medicine*, 1987; 66: 317–326.
2. Murray HW, Brandstetter RD, Lavijne MH. – Ventriculoatrial shunting for hydrocephalus complicating tuberculous meningitis. *Am J Med*, 1981; 70: 895–898.
3. Farr B, Mandell GL. – Rifampin. *Med Clin North Am*, 1982; 66: 157–168.
4. D'Oliveira JG. – Cerebrospinal fluid concentrations of rifampin in meningeal tuberculosis. *Am Rev Respir Dis*, 1972; 106: 432–437.
5. Furesz S. – Chemical and biological properties of rifampicin. *Antibiot Chemother*, 1970; 16: 316–351.
6. Sippel JE, Mikhail IA, Girgis NI, Youssef HH. – Rifampin concentrations in cerebrospinal fluid of patients with tuberculous meningitis. *Am Rev Respir Dis*, 1974; 109: 579–580.
7. Forgan-Smith R, Ellard GA, Newton D, Mitchison DA. – Pyrazinamide and other drugs in tuberculous meningitis. *Lancet*, 1973; 2: 374.
8. Ratcheson RA, Ommaya AK. – Experience with the subcutaneous cerebrospinal fluid reservoir. *N Engl J Med*, 1968; 279: 1025–1031.
9. Lee EL, Robinson MJ, Thong ML, Puthuchery SD, Ong TH, Ny KK. – Intraventricular chemotherapy in neonatal meningitis. *J Pediatr*, 1977; 91: 991–995.
10. Bleyer WA, Pizzo PA, Spence AM, Platt WD, Benjamin DR, Kolins J, Poplack DG. – The Ommaya reservoir. Newly recognized complications and recommendations for insertion and use. *Cancer*, 1978; 41: 2431–2437.
11. Dajez P, Vincken W, Lambelin D, Noterman J, Yourassowski E, Telerman-Toppet N. – Intraventricular administration of rifampicin for tuberculous meningitis. *J Neurol*, 1981; 225: 153–156.