

## Pulmonary sequestration with congenital broncho-oesophageal fistula

W.B.M. Evers\*, R. Vissers\*\*, J.A. van Noord\*

*Pulmonary sequestration with congenital broncho-oesophageal fistula.*  
W.B.M. Evers, R. Vissers, J.A. van Noord.

**ABSTRACT:** Complaints of older patients due to a congenital broncho-pulmonary foregut malformation are rare. A 53 yr old woman presented with this condition. The diagnosis was made by means of oesophagography, which showed a broncho-oesophageal fistula. Using the supplying vessel, identified by angiography, as a guideline, an operation was carried out to correct the anomaly.  
*Eur Respir J., 1990, 3, 1067-1069.*

\* Dept of Pulmonary Diseases and \*\* Dept of Radiology, De Wever Hospital, Heerlen, The Netherlands.

Correspondence: W.B.M. Evers, Antonius Ziekenhuis, Postbus 20.000, NL - 8600 BA Sneek, The Netherlands.

Keywords: Bronchopulmonary foregut; malformation; sequestration.

Received: July 1989; accepted after revision May 2, 1990.

### Case study

A 53 yr old woman consulted her general practitioner complaining of recent fever and pain in the right upper abdomen; she also had a non-productive cough. Because the general practitioner interpreted these complaints as upper abdominal pathology, a radiograph was made of the gastro-oesophageal region (Dept of Radiology, Heerlen, The Netherlands) which, against expectations, showed a communication between the oesophagus and saccular structures in the right lower lung field, the area of the radiological abnormality.

The patient had a history of cavernous pulmonary tuberculosis in 1963, for which she had been adequately treated with tuberculostatic drugs. Until 1981 she had had regular check-ups at the regional out-patient tuberculosis dispensary in Heerlen.

Physical examination, particularly of the lungs, was negative. Erythrocyte sedimentation rate and white cell count were normal, as were the other laboratory tests. Electrocardiogram and spirometry revealed no abnormalities.

An anteroposterior chest radiograph showed a linear shadow in the right paracardiac region, extending from the right hilar area to the diaphragm (fig. 1). The same linear shadow, which incidentally was not located in the tuberculosis-affected area, could be seen on the radiographs made between 1970 and 1981 at the regional out-patient tuberculosis dispensary. Bronchography and bronchoscopy were normal. In view of the communication with the oesophagus, (fig. 2) a diagnosis of pulmonary sequestration was considered very likely; probably extralobar sequestration, since the linear abnormality in the

lower field could be interpreted as a pleural demarcation. An angiogram of the aortic arch showed a large supplying vessel (which was selectively catheterized) extending from the proximal part of the descending aorta to the sequestration (fig. 3). The venous phase demonstrated a vein draining into the superior vena cava. Finally the chest CT scan with contrast enhancement did not show associated anomalies of the pulmonary artery branches and the pulmonary venous return. In the 2 month interval before the operation, a recurrent infection occurred, and an increased density in the right lower field was identified in the area of the already existing radiological abnormality.

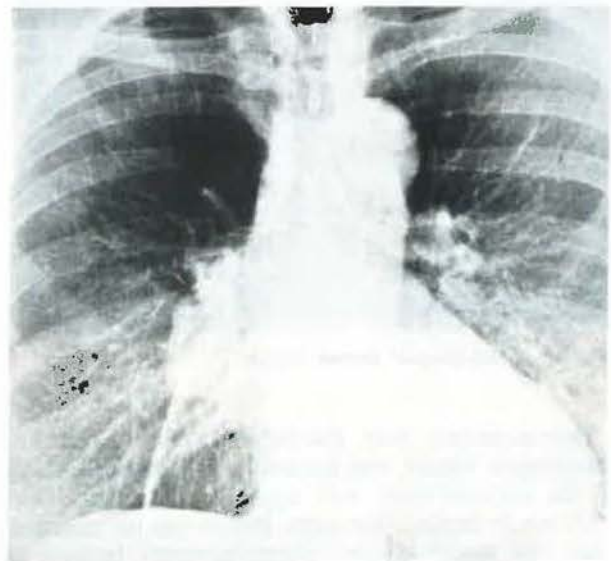


Fig. 1. - Radiograph on admission.



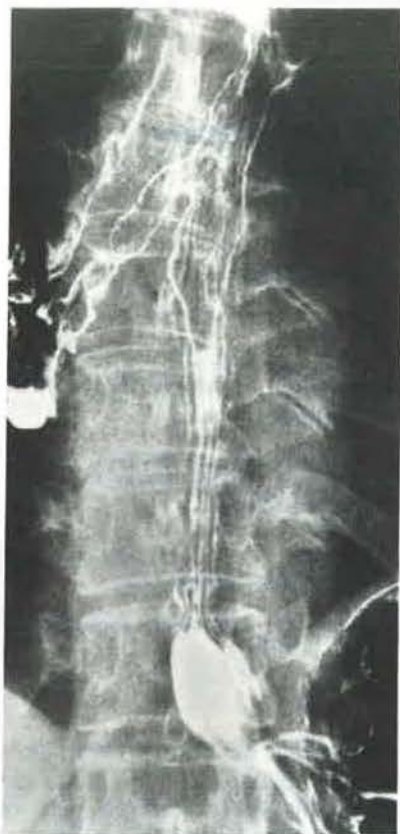

Fig. 2. - Radiograph of oesophagus.

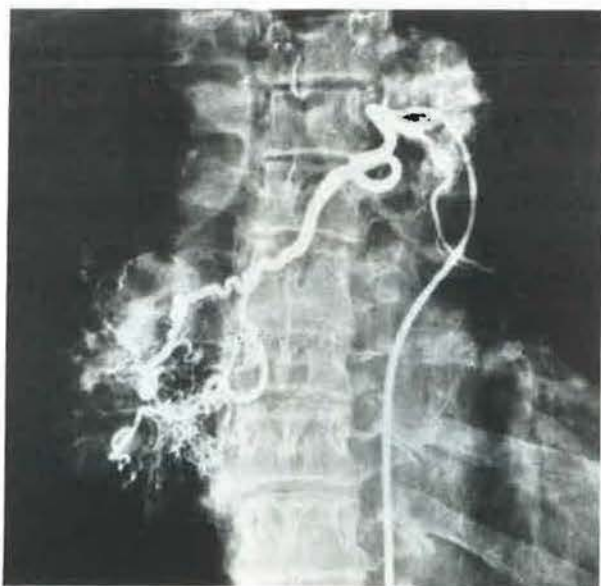


Fig. 3. - Arteriogram of aberrant vessel.

Thoracotomy was performed. The broncho-oesophageal fistula was excised; the supplying artery of the sequestration was ligated; venous drainage could not be located. The sequestration was not removed, since this would involve pneumonectomy because of extensive adhesions to hilar lymph node groups. The post-operative course was uneventful.

In the 4 yr interval between the operation and the last check-up there were no pulmonary complaints. Post-operative radiological check-ups showed only the linear abnormality that was originally present.

### Discussion

A case of extralobar sequestration with a patent communication to the oesophagus is presented: bronchopulmonary foregut malformation. A communication between the digestive tract and part of the lung occurs twice as often in women as in men [1]. In our patient, fever and upper abdominal pain of recent date were the only complaints. The most striking aspect of this case is that it only became symptomatic at the age of 53 yrs, whereas we can assume that the communication had been present from birth. Because pulmonary sequestration, in particular with an open communication to the digestive tract, is a rare anomaly, the potential presence of this condition is usually underestimated. In lingering or recurrent pulmonary infections associated with focal radiological abnormalities, especially if these consistently recur in the same part of the lung, bronchopulmonary sequestration must be considered as a possible diagnosis, even in older patients. It is important to consult previous radiographs, which may support this suspicion if they reveal abnormalities in the same region.

In the above-mentioned circumstances, it is important to consider the possibility of pulmonary sequestration, as adequate treatment can usually be offered. Treatment normally consists of extirpation of the sequestration with or without normal tissue, cleavage of supplying and draining vessels, and excision of an existing oesophageal fistula [2]. Pneumonectomy should be discouraged, because much smaller operations have often been proved to be clinically successful. In this respect it seems therefore important to point out that in our patient, in whom only extirpation of the oesophageal fistula and cleavage of the supplying vessel were performed, no new clinical signs of inflammation occurred in the sequestration during a 4 yr observation period. As discussed by CLEMENTS and WARNER [3] in patients selected for conservative management embolization of the aberrant systemic artery is currently the method of choice [4].

*Acknowledgements:* The authors wish to thank Dr A. Löwenberg, Dr J.J.H. Lamers and Dr E.C.M. Bolle.

### References

1. Heithoff KB, Sane SM, Williams HJ, Jarves CJ, Carter J, Kane P, Brenno WM. - Bronchopulmonary foregut malformations. Aunifying etiological concept. *Am J Roentgenol*, 1976, 126 (1), 46-55.
2. Haller JA Jr, Golladay ES, Pickard LR, Tepas JJ,

Shorter NA, Shermeta DW. – Surgical management of lung bud anomalies: lobar emphysema, bronchogenic cyst, cystic adenomatoid malformation, and intralobar pulmonary sequestration. *Ann Thorac Surg*, 1979, 28, 33–43.

3. Clements BS, Warner JO. – Pulmonary sequestration and related congenital bronchopulmonary-vascular malformations: nomenclature and classification based on anatomical and embryological considerations. *Thorax*, 1987, 42, 401–408.

4. Alivizatos P, Cheatle T, De Leval M, Stark J. – Pulmonary sequestration complicated by anomalies of pulmonary venous return. *J Paediatr Surg*, 1985, 20, 76–79.

*Séquestration pulmonaire avec fistule congénitale broncho-oesophagienne.* W.B.M. Evers, R. Vissers, J.A. van Noord.

RÉSUMÉ: Les plaintes de sujets âgés en rapport avec des malformations congénitales du moignon broncho-pulmonaire sont rares. Une femme de 53 ans s'est présentée dans ces conditions. Le diagnostic a été obtenu par oesophagographie, qui a démontré une fistule broncho-oesophagienne. L'anomalie a été corrigée chirurgicalement grâce à l'utilisation, comme guide, du vaisseau nourricier identifié par angiographie. *Eur Respir J.*, 1990, 3, 1067–1069.