

CASE REPORT

Platypnoea syndrome caused by atrial septal aneurysm

E. Frans, C. Timmermans, M-C. Herregods, H. De Geest,
W. Daenen, M. Delanote, M. Decramer

Platypnoea syndrome caused by atrial septal aneurysm. E. Frans, C. Timmermans, M-C. Herregods, H. De Geest, W. Daenen, M. Delanote, M. Decramer. ©ERS Journals Ltd 1994.

ABSTRACT: A patient with platypnoea after right pneumonectomy and radiotherapy is described. On transoesophageal contrast echocardiography and cardiac catheterization, an atrial septal aneurysm with interatrial right-to-left shunting was detected. Symptoms disappeared after surgical correction.

To the best of our knowledge, this is the first report of a patient with a septal aneurysm and severe platypnoea.

Eur Respir J., 1994, 7, 2082–2084.

Respiratory and Cardiology Division, Dept of Medicine, and Cardiac Surgery Division, Dept of Surgery, Katholieke Universiteit Leuven, Leuven, Belgium.

Correspondence: E. Frans, Dept of Internal Medicine, University Hospital Gasthuisberg, Herestraat 49, B-3000 Leuven, Belgium

Keywords: Atrial septal aneurysm, platypnoea

Received: November 3 1993

Accepted after revision June 12 1994

Dyspnoea is a relatively frequent complaint after pneumonectomy or lobectomy, and is classically due to reduction of alveolar volume and pulmonary vascular bed. Interatrial right-to-left shunting through an atrial septal defect, in the absence of pulmonary hypertension, is an uncommon cause of dyspnoea [1–10]. Patients with the latter disorder have platypnoea. This is defined as dyspnoea induced by upright posture and relieved by recumbency; whilst orthodeoxia is arterial deoxygenation accentuated by upright position and improved by recumbency.

Several mechanisms of right-to-left atrial shunting have been reported: altered right heart compliance [4, 5, 10]; mechanical compression by a hydrothorax increasing the extrinsic pressure on the right atrium [2]; anatomical alterations of the right atrium, such as distortion of the fossa ovalis and of the inferior vena cava, with a change in the direction of blood flow into the right atrium [7, 9].

In this report, we describe a patient with the above-mentioned syndrome after right pneumonectomy and radiotherapy, caused by atrial septal aneurysm. The latter disorder may be associated with systemic or pulmonary embolism [11, 12]. In our patient, it was the cause of a major right-to-left shunt; an association, to the best of our knowledge, not previously described.

Case report

The patient, born in 1926, underwent a right pneumonectomy for a squamous cell carcinoma T2N1M0 in December 1991. Adjuvant radiotherapy was initiated in February 1992. During this session, the patient developed progressive dyspnoea and cyanosis.

On clinical examination and roentgenography, the heart and left lung appeared normal (fig. 1). There was no evidence for radiopneumonitis or infectious disease. On arterial blood gas analysis, we found severe hypoxaemia, relieved by supine position (table 1). Further investigation showed a restrictive pulmonary function deficit due to the pneumonectomy (total lung capacity (TLC) 3.7 l (52% predicted), vital capacity (VC) 2.3 l (54% pred), forced expiratory volume in second (FEV₁) 1.9 l (59% pred), diffusing capacity of the lungs for carbon monoxide (DLCO) 6.2 mmol·min⁻¹·kPa⁻¹ (67% pred).

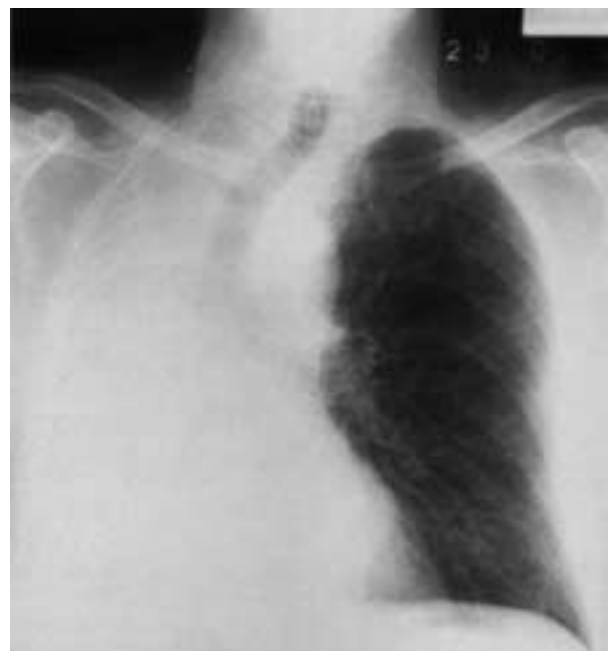


Fig. 1. – Chest X-ray. The heart and left lung appeared normal.

Table 1. – Arterial p_{O_2} (P_{aO_2} kPa) in different positions, before and after resection of the atrial septal aneurysm

	Upright	Supine
Before surgery		
Breathing room air with 3 l $O_2 \cdot \text{min}^{-1}$ supplement	5.7	9.9
Breathing 100% O_2	9.6	44.9
After surgery		
Breathing room air	10.8	12.8
Breathing 100% O_2	54.9	64.4

With pulmonary angiography, pulmonary emboli were excluded. On transoesophageal echocardiography in sitting position, an atrial septal aneurysm with prolapse in the left atrium, was seen (fig. 2). After injection of saline solution, a significant right-to-left shunt was detected. On cardiac catheterization in supine position, the prolapsing aneurysm of the atrial septum was confirmed, together with the right-to-left shunt. The pulmonary artery pressure was normal (26/8 mmHg), and the pressures in the right and left atrium were, respectively, 4 and 3 mmHg, with a cardiac output of 4.3 $l \cdot \text{min}^{-1}$. Measurements during catheterization in upright position were not performed. The right-to-left shunt (across the atrial defect and the physiological shunt in the lung) was calculated at 35% in upright position and 16% in supine position, using the arterial partial pressure of oxygen (P_{aO_2}) during 100% oxygen breathing test.

At surgery, an aneurysm of the fossa ovalis with two small perforations was found. Resection of the aneurysm and closure of the atrial septal defect was performed. After resection, the two small perforations widened substantially during the *in vitro* reconstruction of the bulging position of the aneurysm. Postoperatively, the platypnoea and orthodeoxia were resolved (table 1) and the patient was discharged in good condition. The physiological shunt through the left lung was postoperatively calculated at 13% in upright and 11% in supine position.

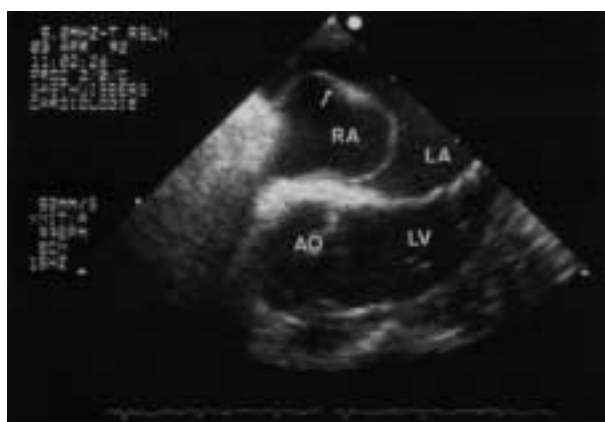

Fig. 2. – Transoesophageal echocardiographic view showing the cavities of the left atrium, (LA) left ventricle, (LV) right atrium, (RA) and aorta, (Ao). An aneurysm of the interatrial septum is bulging into the left atrium (arrow).

Discussion

The syndrome of platypnoea-orthodeoxia is rarely seen in patients with pulmonary or heart disease, and is a known complication after lung surgery. The first report of platypnoea after pneumonectomy by SCHNABEL *et al.* [1] dates from 1956. Other authors reported the same phenomenon in patients after right pneumonectomy, and, more rarely, after left lung resection or lobectomy [2–10]. The small number of reports might be due to inadequate recognition of this unusual disorder.

Patients develop platypnoea a few months to one year after thoracic surgery. Occasionally, the symptom becomes apparent only after severe dehydration or pulmonary embolism. Our patient complained of dyspnoea during radiotherapy, three months after surgery. The shunt occurs across an atrial septal defect, without pulmonary hypertension. In our patient, two small perforations of an aneurysm of the fossa ovalis were found. To the best of our knowledge, this is the first report of the platypnoea syndrome associated with an aneurysm of the atrial septum. There is no clear explanation of the platypnoea after pneumonectomy; the most probable cause being a change of compliance of the right heart in the upright position. This change could result in an increased right atrial pressure, with a right-to-left shunt through an atrial septal defect. However, shunt may also occur without a high pressure gradient, but this requires special anatomical alterations of the vena cava-atrial septum relationship [9]. These changes can develop after right pneumonectomy, as seen in our patient. The apparently contradictory results of the right atrial pressure on catheterization, and the bulging of the atrial septal aneurysm with significant right-to-left shunt during echocardiography, can be explained by the different position of the patient during the investigation: the catheterization was performed in supine position (with a low shunt across the atrial defect), and the echocardiography in sitting position (with a high shunt across the perforations in the bulging aneurysm).

Atrial septal aneurysm, first described by LEV and SAPLIR [13] in 1938, is seen in association with other cardiac abnormalities, but is unusual in an otherwise normal heart. It can be diagnosed by (transoesophageal) echocardiography or angiography, and may be associated with systemic and pulmonary embolism [11, 12].

The clinical suspicion of the right-to-left shunting after lung surgery can be confirmed by tilt table two-dimensional contrast echocardiography in supine and upright position. This examination is able to detect shunting of less than 4% [8]. Cardiac catheterization can be performed to obtain haemodynamic data.

Since this postoperative syndrome is unlikely to be spontaneously reversible, closure of the atrial septal defect is recommended in symptomatic patients. Normally, there is a complete relief of the platypnoea and orthodeoxia after surgical intervention.

Recently, successful transcatheter closure of a patent foramen ovale with a double umbrella with clamshell configuration has been reported [14–16].

References

1. Schnabel TG, Ratto O, Kirby CK, Johnson J, Comroe JH. Postural cyanosis and angina pectoris following pneumonectomy: relief by closure of an interatrial septal defect. *J Thorac Surg* 1956; 32: 246–250.
2. Begin R. Platypnea after pneumonectomy. *N Engl J Med* 1975; 293: 342–343.
3. Roos CM, Romijn KH, Braat MC, Van Leeuwen AM. Posture-dependent dyspnoea and cyanosis after pneumonectomy. *Eur J Respir Dis* 1981; 62: 377–382.
4. LaBresh KA, Pietro DA, Coates O, Khuri SF, Folland ED, Parisi AF. Platypnea syndrome after left pneumonectomy. *Chest* 1981; 79: 605–607.
5. Dlabal PW, Stutts BS, Jenkins DW, Harkleroad LE, Stanford WT. Cyanosis following right pneumonectomy. *Chest* 1982; 81: 370–372.
6. Springer RM, Gheorghide M, Chakko CS, *et al.* Platypnea and interatrial right-to-left shunting after lobectomy. *Am J Cardiol* 1983; 51: 1802–1803.
7. Franco DP, Kinasewitz GT, Markham RV, Tucker WY, George RB. Postural hypoxemia in the postpneumonectomy patient. *Am Rev Respir Dis* 1984; 129: 1021–1022.
8. Seward JB, Hayes DL, Smith HC, *et al.* Platypnea-orthodeoxia: clinical profile, diagnostic work-up, management, and report of seven cases. *Mayo Clin Proc* 1984; 59: 221–231.
9. Van Rossum P, Plokker HW, Ascoop AP. Breathlessness and hypoxaemia in upright position after pneumonectomy. *Eur Heart J* 1988; 9: 1230–1233.
10. Smeenk FW, Twisk SP, Berreklouw E, Gooszen HC, Postmus PE. Dyspnoea after pneumonectomy. *Eur Respir J* 1991; 4: 243–245.
11. Angeli P, Wilansky S, Gaos C, Montazavi A, Boncompagni E, Cooley DA. Prolapsing large aneurysm of atrial septum simulating a right atrial mass. *Cathet Cardiovasc Diagn* 1992; 26: 122–126.
12. Schneider B, Hofmann T, Meinertz T, Hanrath P. Diagnostic value of transesophageal echocardiography in atrial septal aneurysm. *Int J Cardiac Imaging* 1992; 8: 143–153.
13. Lev M, Sapir O. Congenital aneurysm of the membranous septum. *Arch Pathol* 1938; 25: 819–837.
14. Rocchini AP. Transcatheter closure of atrial septal defects. *Circulation* 1990; 82: 1044–1045.
15. Rome JJ, Keane JF, Perry SB, Spevak PJ, Lock JE. Double umbrella closure of atrial defects: initial clinical applications. *Circulation* 1990; 82: 751–758.
16. Landzberg MJ, Bridges ND, Bittl JA, *et al.* Transcatheter closure of atrial septal defects in adults with platypnea-orthodeoxia syndrome. *J Am Coll Cardiol* 1992; 19: 289A.