

Alpha-amylase in resectable lung cancer

P. Lenler-Petersen*, A. Grove**, A. Brock†, R. Jelnes*

Alpha-amylase in resectable lung cancer. P. Lenler-Petersen, A. Grove, A. Brock, R. Jelnes. ©ERS Journals Ltd 1994.

ABSTRACT: Biochemical analysis and immunohistochemical techniques support the theory that hyperamylasaemia in lung cancer is due to amylase production in carcinoma cells. The vast majority of amylase-producing carcinomas are adenocarcinomas with amylase isoenzyme similar to the salivary type. This prospective study assesses α -amylase expression in resectable lung cancer.

Seventy four patients with resectable lung cancer were studied. Amylase activity in tumour tissue was analysed and isoamylase identification performed. Immunohistochemical analysis was performed using a polyclonal rabbit antibody against human salivary amylase.

Hyperamylasaemia occurred in 13 out of 70 patients. Increased amylase activity in tumour tissue was found in 10 out of 52 cases, of which only two were associated with hyperamylasaemia. With the exception of one large cell carcinoma and one squamous cell carcinoma, the tumours were adenocarcinomas. Immunohistochemical analysis revealed amylase expression in seven adenocarcinomas and two adenosquamous carcinomas.

In conclusion, immunohistochemical amylase expression was restricted to carcinomas with adenomatous differentiation. Biochemical analysis confirmed amylase production in 5 of 7 cases examined, the tissue amylase isoenzymes being of salivary type. However, hyperamylasaemia and a slightly increased amylase activity in tumour tissue may be caused by factors other than amylase-producing carcinoma cells.

Eur Respir J., 1994, 7, 941-945.

*Dept of Thoracic Surgery, Aalborg Hospital, Denmark. **Institute of Pathology, Aalborg Hospital, Denmark. †Dept of Clinical Chemistry, University of Aarhus, Randers Central Hospital, Denmark.

Correspondence: P. Lenler-Petersen
Topasdalén 8
DK-8900 Randers
Denmark

Keywords: Amylase
histology
immunohistochemistry
isoenzymes
lung neoplasms
surgery

Received: June 30 1993
Accepted after revision December 31 1993

It is well-known that lung carcinomas, especially small cell carcinomas, may produce various enzymes, tumour antigens and peptide hormones [1, 2]. An association between increased serum amylase and lung carcinomas was first described in 1951, by WEISS *et al.* [3]. Since then, several cases of hyperamylasaemia in patients with lung carcinomas have been published [4-6]. Biochemical analyses of tumour tissue, studies of cell cultures, immunohistochemical techniques, and Northern blot analyses support the theory that amylase is produced by carcinoma cells [4-6]. Hyperamylasaemia in lung cancer has usually been described in case reports, and only a few series have been published [5-8].

Previous studies, mainly performed in Japan, reveal that the vast majority of amylase-producing lung carcinomas are adenocarcinomas [4, 5, 7, 9]. With few exceptions, the tumour-associated amylases are similar to salivary type isoenzymes [4, 5, 7, 9].

This prospective study was undertaken to assess α -amylase expression in primary lung cancers in patients undergoing surgical treatment. Furthermore, we analysed the influence of histological type on amylase expression and isoenzyme pattern.

Materials and methods

Between February 1st, 1989 and September 1st, 1990, 99 consecutive patients underwent thoracotomy due to suspected lung cancer in the Department of Thoracic Surgery. The diagnostic examinations of the patients were carried out at the Department of Pulmonary Medicine or similar departments at regional hospitals. Patients with technically inoperable tumours, disseminated disease or other diseases contraindicating surgery, were excluded from the study.

Seventy four patients, 23 women and 51 men, with resectable primary lung cancer, entered the study. The drop-out rate was 25, due to unresectable tumour, unsuspected metastases from extrathoracic primaries, inflammatory conditions, or mediastinal tumour.

Serum amylase

Blood samples for serum amylase determination were routinely collected before operation. The total catalytic activity of α -amylase (E.C.3.2.1.1) was measured at the

routine clinical chemistry laboratory by mean of a kinetic assay at 37°C, using the Testomar® amylase substrate (Behringwerke, Germany). Calibration was performed as proposed by the Scandinavian Committee on Enzymes [10] (reference interval: 70–300 U·l⁻¹). Samples were not saved for further investigation.

Tissue amylase

The pneumonectomy or lobectomy specimens were received unfixed at the Institute of Pathology, within 15 min after surgical removal. Tumour tissue from adjacent sections, representative and dissected free from necrotic tissue, was obtained for paraffin preparation and biochemical analysis. The latter tissue block, about 1 cm³ was snap-frozen in liquid nitrogen and stored at -20°C until enzyme analysis was performed.

Amylase activity in tumour tissue was measured after homogenization in phosphate-buffered saline. Total catalytic activity of α -amylase in tumour tissue (E.C.3.2.1.1) was assessed by the Phadebas (Pharmacia Sweden) blue starch method at 37°C. Separation of amylase isoenzymes was performed by electrophoresis at pH 8.6 in an agarose gel containing polyacrylamide [11, 12]. Slowly migrating forms corresponding to what has been called "fraction 4 and 5" [13], were classified as pancreatic amylase, and faster migrating forms as salivary type amylase. Tissue amylase activity was measured without knowledge of the histological diagnosis or results of the immunohistochemical studies.

Light microscopy

Formalin-fixed paraffin-embedded sections of the lung tumours were stained with haematoxylin and eosin periodic-acid-Schiff/alcian blue at pH 2.7, with and without diastase pretreatment. Special staining procedures, including immunohistochemical analysis, were used in selected cases.

All sections from the surgical specimens were examined by one of the authors (AG). Histological classification of the tumour was made primarily on the section adjacent to that subjected to biochemical analysis. In the histological classification of lung cancer, we used a slight modification of the World Health Organization (WHO) classification [14], as even a few mucin containing vacuoles were accepted as a sign of adenomatous differentiation.

Immunohistochemistry

Immunohistochemical studies were carried out with the labelled StreptAvidin-Biotin (LSAB) (Dako, Denmark) method using polyclonal rabbit amylase antibodies raised against human salivary amylase. This was produced and evaluated by one of the authors (AB) as described previously [11]. Sections, 5 μ m in thickness, of the formalin-fixed, paraffin-embedded tumour were deparaffinized

with xylene, and a pronase treatment was performed for 5 min. Immunohistochemical analyses were carried out on sections with and without diastase digestion (30 min) of glycogen. Prior to the application of the primary antibody, 3% H₂O₂ in ethanol solution was applied for 30 min in order to block the endogeneous peroxidase. In addition, the sections were treated with 1% bovine albumin in phosphate-buffered saline (PBS) for 15 min. The sections were incubated overnight (18 h) at 4°C with the primary antiserum to human α -amylase (1:10.000). The sections were then incubated with biotinylated swine antirabbit immunoglobulins (1:400) for 30 min at room temperature, after which the LSAB complex was applied for 30 min. Between each incubation, the sections were washed in PBS for 10 min. The peroxidase reaction was developed by adding 3-amino-9-ethyl-carbazole (AEC) (Sigma, St. Louis, USA) for 15 min. The sections were counterstained with Mayer's haematoxylin.

A section from a human parotid gland was run in parallel as a positive control, and nonimmunized rabbit serum on sections pretreated with diastase were used as negative controls.

In order to examine the specificity of the antibody to salivary amylase, sections of formalin-fixed and paraffin embedded tissue from normal human pancreas, liver, uterine cervix and kidney were examined as described above.

Results

Serum amylase

Serum amylase was measured before operation in 70 of the 74 patients. None of the patients had symptoms or signs of pancreatic disease, salivary gland disease or renal insufficiency. None of the patients were febrile before the operation, or suffering from dysregulated diabetes mellitus or severe alcohol abuse. The distribution of total serum amylase activity and its relationship to the various histological types is shown in figure 1. Fifty seven patients had serum amylase levels within the normal range. Hyperamylasaemia (median 354 U·l⁻¹, range

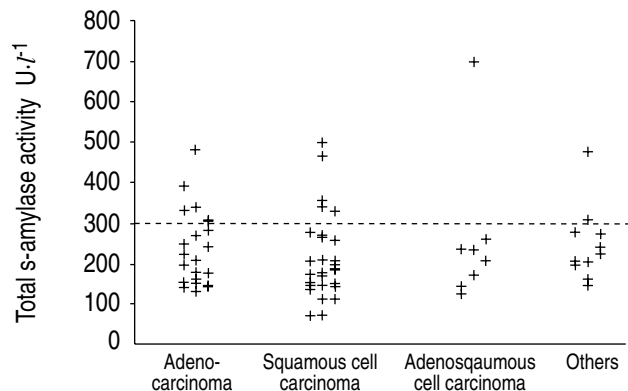


Fig. 1. – Distribution of total serum (s-) amylase activity and relationship to the histological type. Reference interval: 70–300 U·l⁻¹.

306–696 U·l⁻¹) was found in 13 patients. Five had adenocarcinoma, five had squamous cell carcinoma, one adenosquamous cell carcinoma, one carcinoid tumour, and one mixed squamous and small cell carcinoma.

Tumour amylase

In 52 patients, frozen sections of fresh tumour tissue were available for determination of amylase activity. In the remaining 22 cases, biochemical analysis of tumour tissue was omitted, mainly due to small tumour size. The distribution of tumour tissue amylase is presented in figure 2. Amylase activity greater than 1 U·g⁻¹ was considered as increased. The distribution of tumour tissue amylase activity in relation to the various histological types is presented in figure 3. Ten tumours showed amylase activity higher than 1 U·g⁻¹ tissue. In all cases, electrophoresis revealed the amylase to be of salivary type. Apart from one large cell carcinoma and one squamous cell carcinoma, all the tumours were adenocarcinomas. Only two of the 10 cases were associated with hyperamylasaemia. The histological distribution of the 22 tumours, where biochemical analysis was omitted, was 7 adenocarcinomas, 1 adenosquamous carcinomas, 9 squa-

Table 1. – Histological classification of 74 lung tumours

Type	n
Squamous cell carcinoma	31
Adenocarcinoma	
Acinar, papillary or solid	16
Bronchioloalveolar	6
Adenosquamous carcinoma	9
Small cell carcinoma	4
Large cell carcinoma	4
Carcinoid tumour	3
Mixed	
Small/squamous cell carcinoma	1

mous cell carcinomas, 2 carcinoid tumours, 2 small cell carcinomas and 1 mixed squamous and small cell carcinoma.

The distribution of the various histological types in the 74 tumours studied is given in table 1.

Immunohistochemistry

Sixty five carcinomas showed a positive staining reaction of varying degree before diastase treatment. After treatment with diastase, a positive staining reaction for amylase was obtained in 7 adenocarcinomas and 2 adenosquamous carcinomas. A semiquantitative grading was made, based on both the number of reacting cells and the intensity of the staining reaction. Table 2 summarizes the cases with immunohistochemical and/or biochemical amylase expression.

Immunohistochemical staining for amylase showed a positive staining reaction before and after diastase treatment of the control sections from the human parotid gland. Apart from a faintly weaker staining reaction of the ductal epithelium and of secretions in the lumen of the larger ducts, the diastase pretreatment did not change the immunohistochemical staining reaction. No staining reaction was seen when using nonimmunized serum.

The antibody stained acinar cells of the pancreas without differences due to diastase digestion. A moderate or strong positive staining reaction was found before, but not after, diastase treatment in glycogen-containing liver cells, in squamous cell epithelium of normal ectocervix, and muscle cells of blood vessels.

Discussion

This prospective study including 74 patients with surgically resectable lung carcinomas showed hyperamylasaemia in 13 cases. Immunohistochemical analysis revealed amylase reactive tumour cells in seven adenocarcinomas and two adenosquamous cell carcinomas. Amylase expression was restricted to carcinomas with adenomatous differentiation. Biochemical analysis confirmed amylase production in five of the seven cases examined. The isoenzymes of amylase were of salivary type in all cases. Immunoreactive tumour cells were present in only

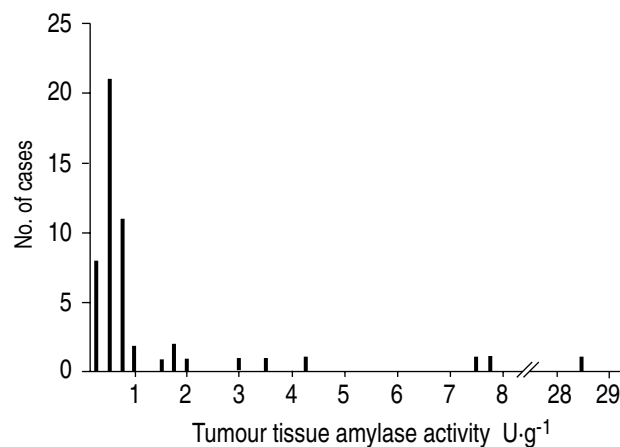


Fig. 2. – Distribution of amylase activity in tumour tissue.

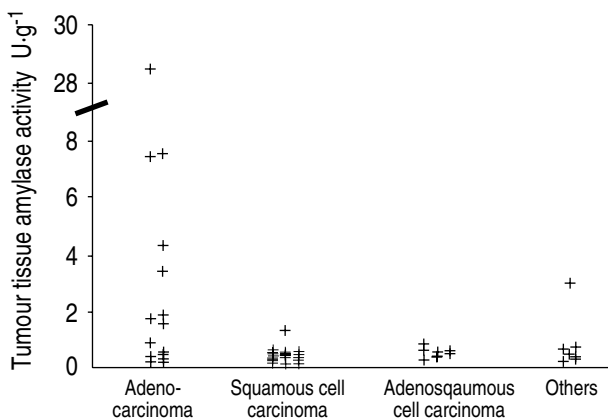


Fig. 3. – Distribution of amylase activity in tumour tissue related to histological type.

Table 2. – Positive immunohistochemical reaction of amylase or amylase activity higher than 1 U·g⁻¹ in tumour tissue among 74 patients with resectable primary lung cancer

Sex	Age yrs	Histology	s-amylase U·l ⁻¹	Tissue U·g ⁻¹	Immunohist. reaction
F	61	Adenocarcinoma	240	28.38	+++
M	66	Adenocarcinoma	150	7.54	++
M	44	Adenocarcinoma	144	NE	++
F	57	Adenocarcinoma	282	7.41	+
M	56	Adenocarcinoma	NE	1.75	+
F	62	Adenocarcinoma	482	1.83	+
F	56	Adenocarcinoma	147	NE	+
F	66	Adenosquamous carcinoma	258	0.60	+
M	71	Adenosquamous carcinoma	144	0.27	+
F	53	Adenocarcinoma	143	1.58	-
M	60	Adenocarcinoma	179	3.40	-
F	54	Adenocarcinoma	329	4.33	-
F	65	Squamous cell carcinoma	71	1.31	-
F	71	Large cell carcinoma	200	2.94	-

Immunohistochemical reaction is semiquantitative: -: negative; +: weak; ++: moderate; +++: strong; NE: not examined; s-amylase: serum amylase.

one case with hyperamylasaemia, and in only half of the cases with increased amylase activity in tumour tissue.

The first series (n=32) of resectable primary lung carcinomas, which were examined biochemically and immunohistochemically for amylase expression, was reported by TOMITA *et al.* [5] in 1988. Previously, amylase-producing lung carcinomas were all detected due to significant hyperamylasaemia. In our study, only 13 patients (18%) had slight hyperamylasaemia. Similar findings were obtained in series, reporting hyperamylasaemia in 6.5–10% of patients with lung cancer [5–8]. With the exception of series by TOMITA *et al.* [5], these studies were not confined to resectable cases.

Our data, as well as previous studies [5, 7], show that hyperamylasaemia cannot be used as a tumour marker for lung cancer, not even among amylase-producing lung carcinomas. An explanation could be that tissue amylase is synthesized, but not secreted by the tumour cells.

In accordance with TOMITA *et al.* [5], we found that amylase-producing lung carcinomas are usually adenocarcinomas or adenosquamous cell carcinomas. Different techniques were used to determine the amylase isoenzyme, but in both studies the amylase was found to be of salivary type. A recent report has disclosed a new amylase in exceptional cases of carcinomas [15]. Usually, however, hyperamylasaemia in a patient with a primary lung tumour indicates that the neoplasm is an adenocarcinoma, or a carcinoma with some degree of adenomatous differentiation.

In the differential diagnosis between primary and metastatic adenocarcinoma of the lung, determination of serum as well as tumour amylase (including determination of amylase isoenzymes) does not seem to be helpful, since ovarian adenocarcinoma may also produce amylase, and may be associated with hyperamylasaemia of salivary type [16–18]. Furthermore, recent immunohistochemical studies have revealed amylase reactive cells in adenocarcinomas of the uterine cervix [19] and thyroid gland [20], as well as in a case of breast carcino-

ma [21]. Further prospective studies are needed to evaluate the clinical significance of the immunohistochemical demonstration of amylase in various carcinomas.

The present study shows that immunohistochemical technique using a polyclonal antibody against human α -amylase is a very sensitive method for amylase detection. Because of cross-reaction with pancreatic type amylase, the method did not allow determination of isoenzyme type in the amylase reactive cells. However, in contrast to the biochemical analysis, it enables one to localize the reaction. A higher sensitivity of the immunohistochemical reaction compared to the biochemical analysis, thus allowing detection of even a few amylase containing tumour cells, may explain why two of the adenosquamous carcinomas in our study with positive immunoreaction did not reveal an increased amylase activity (table 2).

The discrepancies in the detection of amylase by the two methods may also reflect the well-known heterogeneity of lung carcinomas. The results of the biochemical analysis obviously depends on the number of vital tumour cells. Amylase activity may be underestimated, if major parts of the tissue samples are necrotic or consist of normal lung parenchyma with no, or only a few, non-neoplastic, amylase-containing cells [22].

The occurrence of tumour homogenates with increased amylase activity and no immunoreactive tumour cells may have several explanations: neutrophilic inflammation in or adjacent to the tumour may give rise to increased amylase activity, caused by the amylase content in neutrophils [23]. Cells of bronchial epithelium and serous glands have been reported as normal amylase-producing cells [22], and may have an increased production. This may be caused by the infectious or inflammatory process often complicating neoplasms, or by direct invasion of carcinoma cells into the submucosal bronchial glands.

An increased tissue amylase activity in carcinomas without any immunoreactive cells after diastase pretreatment may probably be caused by amylase bound to glycogen [24]. However, glycogen bound amylase seems to reveal

only a slight activity with biochemical or enzyme-histochemical analysis [19].

In conclusion, immunohistochemical amylase expression was restricted to carcinomas with adenomatous differentiation. The isoenzymes of amylase were of the salivary type in all cases. However, hyperamylasaemia and a slightly increased amylase activity in tumour tissue may be caused by factors other than amylase-producing carcinoma cells. Further studies may show whether the phenotypic subgroup defined by the production of α -amylase have a biological impact on the tumour biology, and whether this may be of importance for the handling of the individual patient.

References

1. Anderson WAD, Scotti TM. *In: Synopsis of Pathology*. 9th edn. Saint Louis, CV Mosby Co., 1976; p. 578.
2. Yoshida Y, Mori M, Sonada T, Sakauchi F, Sugawara H, Suzuki A. Ultrastructural, immunohistochemical and biochemical studies on amylase and ACTH producing lung cancer. *Virchows Arch (Pathol Anat)* 1985; 408: 163–172.
3. Weiss MJ, Edmondson HA, Wertman M. Elevated serum-amylase associated with bronchogenic carcinoma. *Am J Clin Pathol* 1951; 21: 1057–1061.
4. Lenler-Petersen P, Vejby-Christensen H, Brock A, Hvidman LE, Axelgaard G. Amylase-producing tumours of the lung. *Ugeskr Laeger* 1989; 151: 83–85.
5. Tomita N, Matsuura N, Horii A, *et al.* Expression of α -amylase in human lung cancers. *Cancer Res* 1988; 48: 3292–3296.
6. Maeda M, Otsuki M, Yuu H, Saeki S, Yamasaki T, Baba S. Salivary-type hyperamylasemia in primary lung cancer: observation of a possible precursor of the salivary-type isoamylase. *Eur J Cancer Clin Oncol* 1982; 18: 123–128.
7. Sirsat AV, Talavdekar RV, Shrikhande SS, Vyas JJ. Serum isoamylases in lung cancer correlation with histological features of the tumour. *Ind J Cancer* 1976; 13: 267–271.
8. McGeachin RL, Adams MR. Serum amylase and lung cancer. *Cancer* 1957; 10: 497–499.
9. Nishiki M, Okumichi T, Yamane M, *et al.* Ectopic production of salivary-type amylase associated with bronchogenic carcinoma: case report and review of the literature. *Hiroshima J Med Sci* 1984; 33: 331–335.
10. Gerhardt W, Waldenstrom J, Horder M, *et al.* SCE Nordic alpha-amylase study. II: Assessment of proposed calibration procedure. A report by the Scandinavian Committee on Enzymes (SCE). *Scand J Clin Lab Invest* 1986; 46: 465–469.
11. Brock A. Amylase in duodenal aspirates: relations between concentration, activity and isoenzyme pattern. *Scand J Clin Lab Invest* 1987; 47: 725–730.
12. Skude G. Electrophoretic separation, detection and variation of amylase isoenzymes. *Scand J Clin Lab Invest* 1975; 35: 41–47.
13. Magid E, Horsing M, Rune SJ. On the quantitation of isoamylases in serum and the diagnostic value of serum pancreatic-type amylase in chronic pancreatitis. *Scand J Gastroenterol* 1977; 12: 621–627.
14. The World Health Organization. Histological typing of lung tumours. Second edition. *Am J Clin Pathol* 1982; 77: 123–136.
15. Tomita N, Horii A, Doi S, *et al.* A novel type of human α -amylase produced in lung carcinoid tumor. *Gene* 1989; 76: 11–18.
16. Henriksen R, Brock A. Amylase activity and fast-migrating amylase isoenzymes in serum and cyst fluid from patients with ovarian neoplasms. *Acta Obstet Gynecol Scand* 1988; 67: 65–70.
17. Ueda G, Yamasaki M, Inoue M, Tanaka Y, Abe Y, Ogawa M. Immunohistochemical study of amylase in common epithelial tumors of the ovary. *Int J Gynecol Pathol* 1985; 4: 240–244.
18. Griffin NR, Wells M. Immunolocalisation of α -amylase in ovarian mucinous tumours. *Int J Gynecol Pathol* 1990; 9: 41–46.
19. Griffin NR, Wells M, Fox H. Modulation of the antigenicity of amylase in cervical glandular atypia, adenocarcinoma *in situ* and invasive adenocarcinoma. *Histopathol* 1989; 15: 267–279.
20. Higashiyama M, Doi S, Tomita N, *et al.* Immunohistochemical analysis of amylase isoenzymes in thyroid cancer. *J Clin Pathol* 1991; 44: 144–146.
21. Inaji H, Koyama H, Higashiyama M, *et al.* Immunohistochemical, ultrastructural and biochemical studies of an amylase-producing breast carcinoma. *Virchows Arch (Pathol Anat)* 1991; 419: 29–33.
22. Hayashi Y, Fukayama M, Koike M, Nakayama T. Amylase in human lungs and female genital tract. Histochemical and immunohistochemical localization. *Histochemistry* 1986; 85: 491–496.
23. Zakrzewska I, Prokopowicz J. The activity of leucocytic alpha-amylase in leukemias. *Folia Haematol (Leipzig)* 1983; 110: 42–47.
24. Loyter A, Schramm M. The glycogen-amylase complex as a means of obtaining highly purified α -amylase. *Biochim Biophys Acta* 1962; 65: 200–206.