

CASE REPORT

Cardiac angiosarcoma revealed by lung metastases

J-F. Bic*, O. Fade-Schneller*, B. Marie**, J-L. Neimann†, D. Anthoine*, Y. Martinet*††

Cardiac angiosarcoma revealed by lung metastases. J-F Bic, O. Fade-Schneller, B. Marie, J-L Neimann, D Anthoine, Y Martinet. ©ERS Journal Ltd 1994.

ABSTRACT: Cardiac angiosarcoma is a rare tumour with very poor prognosis especially in patients with metastatic disease. We present the case of a 43 year old patient with angiosarcoma revealed by open lung biopsy for multiple pulmonary metastases.

Cardiac symptoms were limited to a moderate pericarditis and no echocardiographic sign of heart tumour was observed. The clinical outcome was rapidly fatal despite chemotherapy. The cardiac primary tumour was diagnosed at autopsy.

We emphasize the difficulties of diagnosing cardiac angiosarcoma and confirm the limited value of echocardiography for this diagnosis.

Eur Respir J., 1994, 7, 1194–1196.

*Clinique Pneumologique, Hôpital de Brabois, CHU de Nancy, Vandoeuvre-lès-Nancy, France. **Service d'Anatomie Pathologique, Hôpital Central, CHU de Nancy, Nancy, France. †Service de Cardiologie, Clinique Claude Bernard, Metz, France. ††INSERM U14, Vandoeuvre-lès-Nancy, France.

Correspondence: Y. Martinet, Clinique Pneumologique, CHU de Nancy, 54511 Vandoeuvre-lès-Nancy, France.

Keywords: Angiosarcoma, heart neoplasm, lung metastases.

Received: May 5 1993

Accepted after revision October 13 1993

Case report

In February 1992, a 43 year old male patient who was a current smoker working in a steel factory, suddenly fainted for a few minutes. After recovery, the patient noticed moderate atypical chest pain without symptoms of cardiac failure. The pain was related to a pericarditis with moderate effusion. The patient was initially treated with furosemide (40 mg·day⁻¹) and ketoprofen (300mg·day⁻¹). Roxithromycin (300 mg·day⁻¹) was prescribed, 4 days after onset, due to the appearance of

fever and cough with purulent and blood-streaked expectoration. Chest radiography (fig. 1a) revealed cardiac enlargement with right pleural effusion and bilateral basal linear shadows. Echocardiography confirmed the presence of a pericardial effusion.

In the absence of any significant clinical improvement, the patient was transferred, 21 days after onset, to our department. On admission, the patient was afebrile, had lost 2 kg, and complained of dyspnoea (stage 1; American Thoracic Society (ATS) scale [1]) with haemoptysis. Physical examination revealed bilateral basal pulmonary

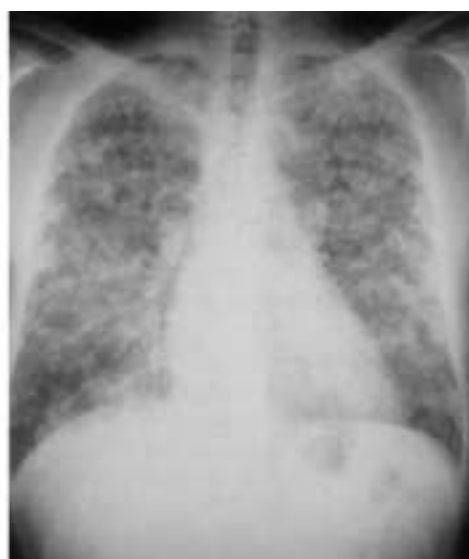
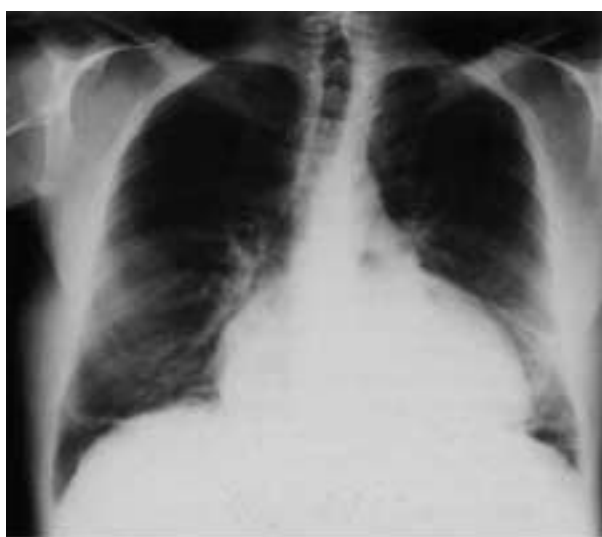
Fig. 1. – a) Chest radiograph, at time of admission, showing cardiac enlargement, right pleural effusion, and bilateral basal linear shadows. b) Chest radiograph, three weeks later, showing cardiac enlargement, bilateral pleural effusion, bilateral nodular infiltrates.

crackles, cardiac apical systolic murmur, and increased liver size. Chest X-ray showed cardiomegaly, bilateral pleural effusion, and bilateral diffuse nodular infiltrates (fig. 1b). At fiberoptic bronchoscopy, blood was noticed in the two upper bronchi, without endobronchial lesion. Bronchial and transbronchial biopsies were normal. No malignant cells were recovered by bronchoalveolar lavage, and bacteriological and mycological investigations were negative. Spirometry showed a restrictive pulmonary pattern: total lung capacity (TLC) 42%, vital capacity (VC) 64%, and forced expiratory volume in one second (FEV_1) 63% of normal predicted values [2], with resting arterial oxygen tension (P_{aO_2}) 8.6 kPa and resting arterial carbon dioxide tension (P_{aCO_2}) 4.8 kPa. Echocardiography showed the persistence of a moderate pericardial effusion (≈ 300 ml), with moderate mitral and tricuspid regurgitation [3], and normal ventricular kinetics. There was no evidence of intracardiac abnormality. Blood tests showed signs of nonspecific inflammation. In the absence of a specific diagnosis, an open lung biopsy was performed, leading to the diagnosis of angiosarcoma. Light microscopic examination of the pulmonary nodules and samples of the cardiac tumour obtained later at autopsy showed a diffuse process with highly pleomorphic malignant endothelial-appearing cells forming multiple thin-walled vascular-like spaces (fig. 2). Factor VIII-related antigen was positive by immunoperoxidase staining. In a few tumour cells, Weibel-Palade bodies, *i.e.* tubular structures found in normal endothelium were revealed electronmicroscopically. Despite chemotherapy prescribed according to European Organization for Research and Treatment of Cancer (EORTC) [4] (doxorubicin 75 mg·m⁻² on day 1), the patient died 8 days after its initiation and, thus, three months after the first symptoms.

At autopsy, a pleural left-sided haemorrhagic effusion was noticed. Both lungs were heavy, exuded blood-tinged fluid when pressure was applied to the cut surface, and were sprinkled with countless haemorrhagic tumoral nodules. The pericardial cavity was completely obliterated by fibrous adhesions. A large haemorrhagic necrotic mass had destroyed the external wall of the right atrium, and part of the diaphragmatic and lateral wall of the right ventricle (fig. 3). There was no significant obstruction of the right atrial and ventricular

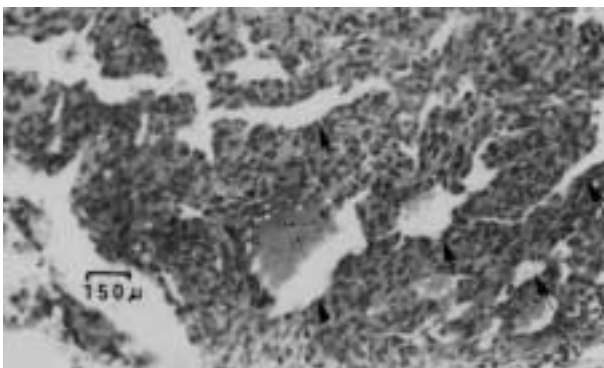


Fig. 2. — Open lung biopsy: metastasis of angiosarcoma with multiple irregularly-shaped blood vessels (—>) lined by neoplastic endothelial cells. Haematoxylin and eosin (H.E.) stain, magnification $\times 160$. (Bar line: 150 μ m).

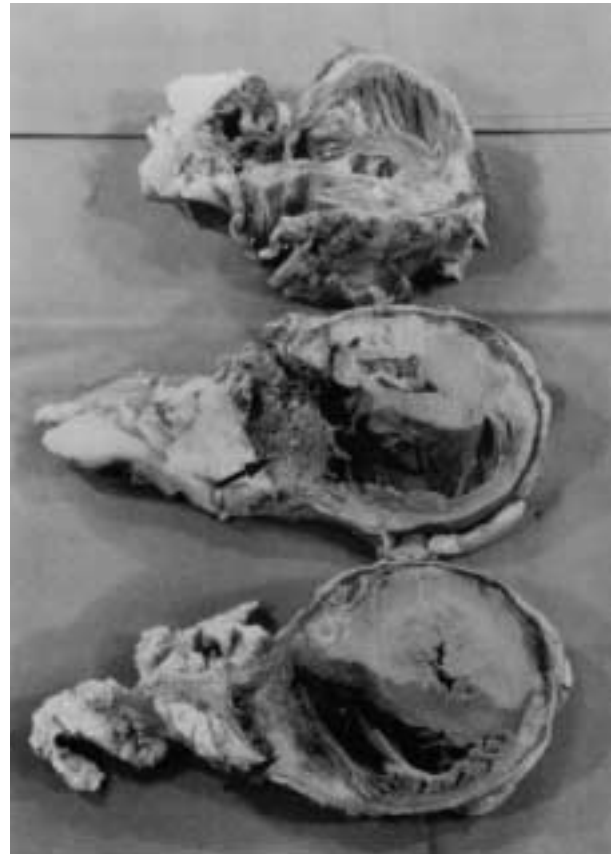

Fig. 3. — Necropsy: heart, horizontal section after formalin fixation, showing tumoral infiltration (—>) of the right atrial and ventricular wall.

cavities. Several small neoplastic emboli were detected by microscopic examination. Two metastases were present in the liver.

Discussion

Despite being the most frequent malignant primary tumour of the heart, angiosarcoma is a rare disease, with a poor prognosis [5–7]. About 175 cases have been published since the first description in 1889 [5]. Due to a very high metastatic potential (especially directed to lung and liver) and despite improvement in medical imaging resulting in earlier diagnosis, therapeutic results remain disappointing.

In the present case, the cardiac tumour was diagnosed only at autopsy, so the evolution of cardiac symptomatology was unusual: 1) in most cases, severe pericardial effusion leads to cardiac tamponade requiring repeated pericardial paracentesis. The pericardial effusion of our patient was well-tolerated during the course of the disease, and the initial symptoms were limited to moderate chest pains; and 2) despite four successive echocardiographies performed by three different physicians the diagnosis of intracardiac tumour was never suggested. The echocardiograms were re-examined after the diagnosis was established, and no evidence of intracardiac tumour was observed. The limited sensitivity of echocardiography

in the diagnosis of cardiac tumours has been observed previously. Nuclear magnetic resonance imaging and transoesophageal echocardiography appear to be more promising, due to their better sensitivity and resolute capacity [8–11]. No definitive interpretation has been given to explain this discrepancy; different and atypical echogenicity and the concentric development of the tumour have been suggested as contributory factors. Despite the absence of direct proof of large emboli in the lung at necropsy, it is possible that the initial symptoms (fainting with atypical chest pain, pleural effusion) were due to tumour emboli. Thus, our observation is unusual in respect to three facts: diagnosis revealed by lung metastases, spontaneous regression of pericardial effusion and absence of typical signs at echocardiography. We recommend that a primary heart tumour should be suspected in patients with lung metastases and pericardial effusion.

Exposure to various substances (thorium dioxide, pesticides derived from arsenic and vinyl chloride) seems to contribute to the occurrence of hepatic angiosarcomas [12]. Soft tissue and bone angiosarcomas following therapeutic irradiation have also been mentioned [12]. In contrast, no risk factors have been proposed in cardiac angiosarcoma. In the present observation, a possible role of exposure to X-rays may be suspected, since the patient worked in a factory specializing in X-ray checking of metal parts. However, no accident resulting in abnormal exposure to radiation was reported in the plant where the patient had worked for 2 yrs.

The treatment of cardiac angiosarcoma remains disappointing, especially in metastatic disease, with a 6 months median survival [13–15]. Surgery may provide a longer survival in patients without metastasis. In patients with metastatic disease, the treatment consists of chemotherapy; however, with poor results [7–14].

Acknowledgements: This work was supported in part by the "Centre Lorrain d'Etude et de Recherche sur le Cancer du Poumon".

References

1. Comstock GW, Tockman MS, Helsing KJ, Hennesy KM. Standardized respiratory questionnaires: comparison of the old with the new. *Am Rev Respir Dis* 1979; 119: 45–53.
2. CECA. Aide mémoire of spiographic practice for examining ventilatory function. 2nd ed. Luxembourg Industrial Health and Medicine, 1971; Series No. 11.
3. Feigenbaum H. Acquired valvular heart disease. In: Braunwald E, ed. *Heart Disease: a Text book of Cardiovascular Medicine*. Philadelphia, W.B. Saunders Co, 1992; pp. 81–89.
4. Santoro A, Rovesse J, Steward W, *et al.* A randomized EORTC study in advanced soft tissue sarcomas: ADM vs ADM+IFX vs CYVADIC. *Proc Am Soc Clin Oncol* 1990; 9: 309.
5. Glancy DL, Morales JB, Roberts WC. Angiosarcoma of the heart. *Am J Cardiol* 1968; 21: 413–419.
6. Janigan DT, Hasain A, Robinson NA. Cardiac angiosarcomas. *Cancer* 1986; 57: 852–859.
7. Herrmann MA, Shankerman RA, Edwards WD, Shub C, Shaff HV. Primary cardiac angiosarcoma: a clinicopathologic study of six cases. *J Thorac Cardiovasc Surg* 1992; 103: 655–664.
8. Come P, Riley M, Markis J, Malagold. Limitations of echocardiographic techniques in evaluation of left atrial mass. *Am J Cardiol* 1981; 48: 947–953.
9. Aouate Ph, Artigon JY, Rovary X, Orion L. Apport de l'exploration par résonance magnétique nucléaire dans l'angiosarcome auriculaire droit. *Arch Mal Coeur* 1988; 81: 1543–1546.
10. Freedberg RS, Kronzon I, Ramancik WM, Liebeskind D. The contribution of magnetic resonance imaging to the evaluation of intracardiac tumors diagnosed by echocardiography. *Circulation* 1988; 77: 96–105.
11. Frohwein SC, Karalis DG, McQuillan JM, Ross JJ. Preoperative detection of pericardial angiosarcoma by transesophageal echocardiography. *Am Heart J* 1991; 3: 874–875.
12. Enzinger FM, Weiss SW. Malignant vascular tumors. In: Stamathis G, ed. *Soft Tissue Tumours*. St Louis, C.V. Mosby Co., 1988; pp. 545–580.
13. Spragg RG, Wolf PL. Angiosarcoma of the lung with fatal pulmonary hemorrhage. *Am J Med* 1983; 74: 1072–1076.
14. Vergnon JM, Vincent M, Perinetti M, Cordier JF, Brune J. Chemotherapy of metastatic primary cardiac sarcomas. *Am Heart J* 1985; 110: 682–684.
15. Zwaveling JM, Teding van Berkout F, Harreveld GT. Angiosarcoma of the heart presenting as pulmonary disease. *Chest* 1988; 94: 214–218.