

CASE STUDY

Plastic bronchitis

J.Y. Park, A.A. Elshami*, D.S. Kang**, T.H. Jung

Plastic bronchitis. J.Y. Park, A.A. Elshami, D.S. Kang, T.H. Jung. ©ERS Journals Ltd 1996.

ABSTRACT: Plastic bronchitis is generally associated with some type of pulmonary disease and improves either spontaneously or with medical therapy. We present a case of plastic bronchitis with no known cause.

The patients' symptoms were not responsive to medical therapy but were relieved after right middle lobectomy.

Eur Respir J., 1996, 9, 612-614.

Division of Pulmonary Medicine, Dept of Internal Medicine, Diagnostic Radiology. *Division of Pulmonary and Critical Care Medicine, Dept of Internal Medicine, University of Pennsylvania Medical Center, Philadelphia, USA. **School of Medicine, Kyungpook National University, Taegu, Korea.

Keywords: Mucoid impaction
plastic bronchitis

Received: April 19 1995

Accepted after revision November 3 1995

Plastic bronchitis, also known as fibrinous bronchitis or pseudomembranous bronchitis, denotes the presence of inspissated bronchial casts that may be coughed up or found at bronchoscopy or in surgical specimens [1-3]. Bronchial casts are generally associated with diffuse bronchial hypersecretory disorders, such as asthma or mucoviscidosis [4-6], and are also reported to be present in pneumonia [4], pericardial effusion [5], and heart failure [7]. Plastic bronchitis is usually self-limited or responsive to medical therapy, with a good prognosis [1-5].

We report a case of plastic bronchitis not related to a specific bronchopulmonary disease. Our case was not responsive to medical therapy but improved after right middle lobe resection.

Case report

A 17 year old man was admitted to the hospital with a one month history of cough and yellow sputum, which were not relieved by antibiotics and the usual expectorants. He had been relatively healthy despite being on digoxin and diuretics following heart surgery for Tetralogy of Fallot 5 yrs prior to admission. On examination, the patient appeared acutely and chronically ill. Blood pressure was 110/70 mmHg, pulse rate 80 beats·min⁻¹, respiratory rate 20 breaths·min⁻¹, and body temperature 37°C. A grade III systolic murmur was heard at the cardiac apex and inspiratory crackles were present over both lower lung fields. There was no pitting oedema or clubbing. White blood cell count was 6,500 cells·mm⁻³, with 52% neutrophils, 42% lymphocytes, 2% monocytes

and 4% eosinophils. Sputum cultures grew alpha-haemolytic streptococci but no fungi or other pathogens.

Chest roentgenogram showed bilateral patchy infiltrations with cardiomegaly. The heart size was unchanged compared with that recorded 2 months before admission (fig. 1a). High resolution computed tomography (HRCT) scan showed bilateral patchy consolidations, both centrally and peripherally. No evidence of interstitial oedema was present (fig. 1b). Echocardiography revealed left atrial and ventricular enlargement with mitral regurgitation. These findings were unchanged compared to the findings 6 months prior to admission. Spirometry was normal, with a forced vital capacity (FVC) of 4.01 L (102% of predicted), forced expiratory volume in one second (FEV₁) of 3.52 L (102% pred), and FEV₁/FVC of 87%. Transfer factor of the lungs for carbon monoxide was 20.4 mL·mm⁻¹·mmHg⁻¹ (74% pred). Breathing room air, arterial blood pH was 7.38, arterial carbon dioxide tension (P_{a,CO_2}) 4.8 kPa (36.2 mmHg) and arterial oxygen tension (P_{a,O_2}) 11.4 kPa (85.5 mmHg). Fibreoptic bronchoscopy disclosed widespread hyperaemic mucosa with viscid purulent secretion in the large bronchi on both sides. At this time, the patient was considered to have pneumonia with retained secretions. Treatment with antibiotics and chest physiotherapy was associated with clinical improvement. Complete roentgenographic resolution followed and the patient was discharged.

One month following discharge, the patient was admitted again with expectoration of mucoid plugs and dyspnoea. He denied fever, haemoptysis, or orthopnoea. White blood cell count was 8,500 cells·mm⁻³, with 58% neutrophils, 38% lymphocytes, 2% monocytes, and 2% eosinophils. Immunoglobulin E (IgE) was within normal limits. Smears and cultures for fungi and mycobacteria were negative. Skin test as well as serum precipitins against *Aspergillus fumigatus* were negative. Sweat chloride concentration was 17 mEq·L⁻¹. Chest roentgenogram showed bilateral

Correspondence: J.Y. Park, Division of Pulmonary Medicine, Dept of Internal Medicine, Kyungpook National University, Samduk 2-Ga 50, Taegu, 700 412 Korea

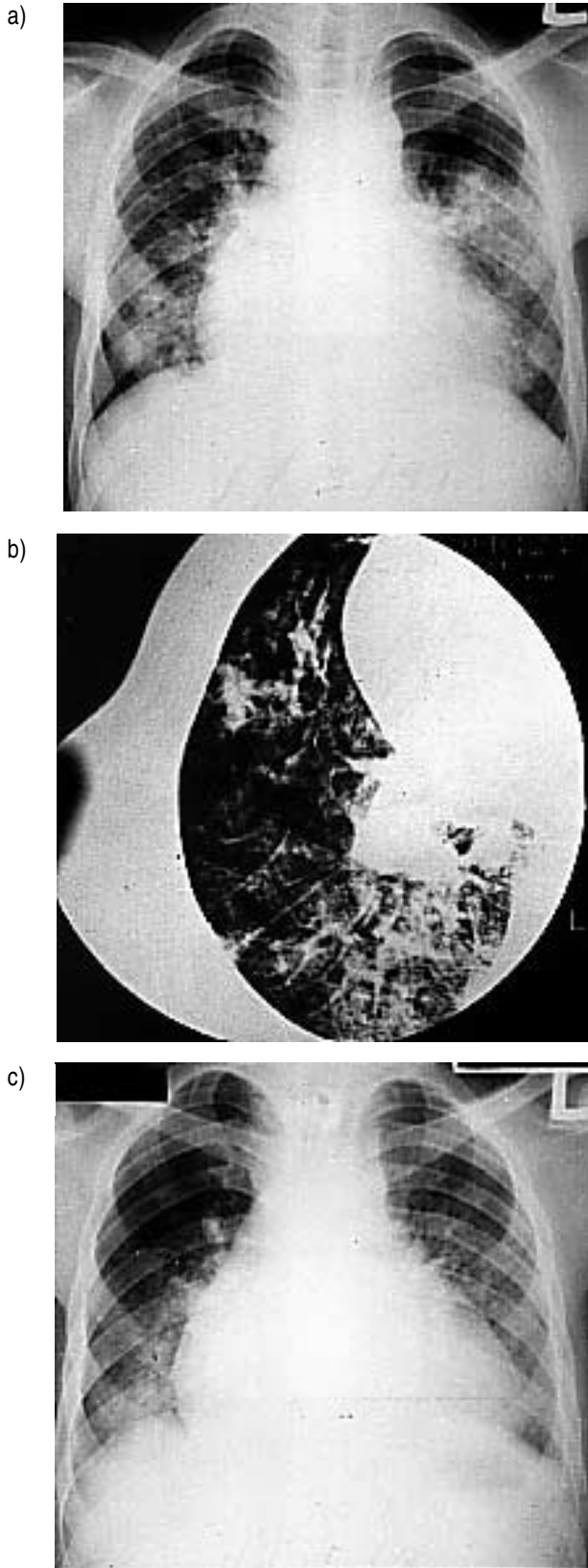


Fig. 1. — a) Chest roentgenogram at the first admission shows bilateral patchy infiltration with cardiomegaly. b) High resolution computed tomographic scan at the first admission shows patchy consolidations with preservation of normal lung regions. c) Chest roentgenogram at subsequent admission shows similar findings to those of the first admission.

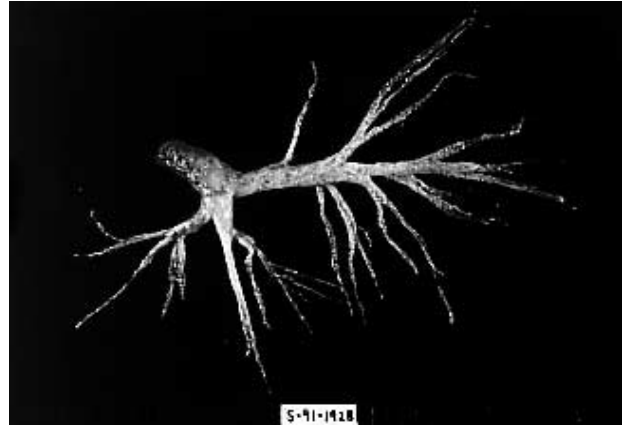


Fig. 2. — Cast, measuring 12×1.2 cm, extracted from the right main bronchus by bronchoscopy.

patchy infiltrations (fig. 1c), similar to the findings at the first admission. Pulmonary function tests revealed no ventilatory impairment. At bronchoscopy, thick and tenacious secretions were present in all large bronchi on both sides. It was difficult to aspirate them. No obstructing lesions were seen. Despite therapy with β -agonist, antibiotics, prednisone 60 oral mg·day⁻¹, intrabronchial instillation of acetylcysteine (Mucomist®) and physical therapy, his condition continued to deteriorate.

One month after admission, the right main bronchus was completely obstructed by bronchial casts. Multiple branching casts, measuring 12×1.2 cm (fig. 2), were extracted from the right main and right middle lobe bronchi. The casts appeared to originate from the right middle lobe bronchi. On histological examination, the casts were composed of mucus and fibrinous material, containing moderate numbers of lymphocytes and foamy histiocytes. Eosinophils and Charcot-Leyden crystals were absent. Cultures of the casts were negative. Trans-bronchial biopsy specimens showed normal alveolar architecture with mild interstitial fibrosis and abundant mucus-laden macrophages. In spite of serial removal of casts, mechanical ventilation was required because of severe hypoxaemia. A right middle lobectomy was performed. Pathological examination showed mild infiltration of chronic inflammatory cells in the submucosa. The patient has not complained of bronchial casts in the 4 yrs since surgery.

Discussion

Plastic bronchitis is defined as the presence of inspissated bronchial casts that may be expectorated or found at bronchoscopy or in surgical specimens [1–3]. Bronchial casts are usually associated with diffuse bronchial hypersecretory disorders, such as mucoid impaction, asthma, allergic bronchopulmonary aspergillosis or mucoviscidosis [4–6], and are also reported to be present in pneumonia [4], pericardial effusion [5], and heart failure [7].

Plastic bronchitis occurs at all levels of the tracheo-bronchial tree, but is more common in the lower lobe. Mucoid impaction differs from plastic bronchitis in several ways: the plugs tend to be in the large segmental

bronchi of the upper lobe; they are generally tightly adherent to the wall; and they are retained rather than being expectorated. Mucoïd impaction has a strong correlation with asthma [4]. SANERKIN *et al.* [8] reviewed the histopathological features of mucoïd plugs and bronchial casts in four conditions, *i.e.* bronchial asthma, mucoïd impaction, allergic bronchopulmonary aspergillosis, and plastic bronchitis. All casts and mucus plugs were essentially identical on the basis of pathological findings. They hypothesized that these disorders are based on a common allergic response involving the bronchial mucosa, *i.e.* an allergic bronchitis that may be complicated by an episode of extensive cast formation (plastic bronchitis) or by mucoïd impaction. MORGAN and BOGOMOLETZ [9], however, noted that plastic bronchitis is a clinical rather than a pathologic entity, and that, while these disorders, such as mucoïd impaction, plastic bronchitis and allergic bronchopulmonary aspergillosis overlap considerably, they are not identical. These investigators emphasized that most cases of plastic bronchitis are not associated with asthma and that allergy is only one of its causes. In our case, there was no clinical or pathological evidence suggestive of asthma. Moreover, the negative results of the precipitins or skin test reactivity to *Aspergillus* antigen are not consistent with allergic bronchopulmonary aspergillosis.

BOWEN *et al.* [5] suggested that an elevated pulmonary venous pressure, present in the patient with pericardial effusion, may play a possible role in the pathogenesis of cast formation. In our patient, no specific therapy was given to lower pulmonary venous pressure, and we assumed that pulmonary venous pressure remained elevated throughout the study. BETTMANN [7] suggested that cardiomegaly due to organic heart disease may predispose to plastic bronchitis by external compression of a bronchus. The fact that our patient has not complained of bronchial cast in the 4 yrs since his right middle lobectomy (in spite of persistent cardiomegaly) suggests that the external compression is not an important contributory factor in this patient.

Therapy for plastic bronchitis consists of specific measures to treat the underlying pulmonary condition as well as manoeuvres designed to remove or facilitate the expectoration of bronchial casts [4]. The role of corticosteroids is uncertain, although they are likely to be beneficial in any allergic-mediated reaction [2]. Aerosolized acetylcysteine or bronchoscopic facilitation of drainage may

be of benefit [1, 10]. Prevention of reoccurrence of the disease has been achieved by inhalation of heparin in one case [11]. Bronchoscopic removal of the casts may be beneficial but is difficult, especially in cases of unusually large bronchial casts, because of their friability and adherence to the bronchial mucosa [3, 4]. However, we were able to successfully remove the casts by gentle pulling. Although some patients have been documented who required assisted ventilation or who died from suffocation [1, 5], plastic bronchitis is usually self-limited or responsive to medical therapy, with a good prognosis [1–5]. Our patient did not respond to oral corticosteroid or intrabronchial instillation of acetylcysteine and continued to deteriorate despite medical therapy. However, he improved following a right middle lobectomy.

References

1. Johnson SR, Sita-Lumsden EG. Plastic bronchitis. *Thorax* 1960; 15: 325–332.
2. Jett JR, Tazelaar HD, Keim LW, Ingrassia TS. Plastic bronchitis: an old disease revisited. *Mayo Clin Proc* 1991; 66: 305–311.
3. Liston SL, Porto D, Siegel LG. Plastic bronchitis. *Laryngoscope* 1986; 96: 1347–1351.
4. Fairshter RD, Riley CA, Hewlett RI. Large bronchial casts. *Arch Intern Med* 1979; 139: 522–525.
5. Bowen A, Qudjhane K, Odagiri K, Liston SL, Cumming WA, Oh KS. Plastic bronchitis: large, branching, mucoïd bronchial casts in children. *Am J Roentgenol* 1985; 144: 371–375.
6. Sulavik SB. Bronchocentric granulomatosis and allergic bronchopulmonary aspergillosis. *Clin Chest Med* 1988; 9: 609–621.
7. Bettmann M. Report of a case of fibrinous bronchitis, with a review of all cases in the literature. *Am J Med Sci* 1902; 123: 304–329.
8. Sanerkin NG, Seal RME, Leopold JG. Plastic bronchitis, mucoïd impaction of bronchi and allergic bronchopulmonary aspergillosis, and their relationship to bronchial asthma. *Ann Allergy* 1966; 24: 586–594.
9. Morgan AD, Bogomoletz W. Mucoïd impaction of bronchi in relation to asthma and plastic bronchitis. *Thorax* 1968; 23: 356–369.
10. Urschel HC, Paulson DL, Shaw RR. Mucoïd impaction to bronchi. *Ann Thorac Surg* 1966; 2: 1–16.
11. Hammelmann G, Konietzko N. Bronchitis plastica: Differentialdiagnose und therapeutische Ansätze. *Prax Klin Pneumol* 1987; 41: 943–945.